

IMMEDIATE RESULTS OF BYPASS GRAFTING OF THE TERRITORY OF THE RIGHT CORONARY ARTERY USING THE «PENZA CORONARY TECHNOLOGY»

ROSSEIKIN E.V., BAZYLEV V.V., KOBZEV E.E., VOEVODIN A.B.,
BATRAKOV P.A., NACHKEBIA B.R., SENZHAPOV I.YA.

Federal Centre of Cardiovascular Surgery under the RF Ministry of Public Health, Penza, Russia

Coronary artery bypass grafting (CABG) is known to be an effective method of treatment for multivessel obstructive coronary disease with low rates of reintervention and excellent long-term survival and freedom from angina. Graft patency lies at the heart of its procedural success and durability, which in its turn largely depends on the appropriate choice of the conduit, as well as the target coronary artery (CA). It should be mentioned that patency of one and the same conduit used for bypass grafting of the territory of either the left or right coronary artery (LCA and RCA, respectively) may differ, which is probably determined by differences in physiology, size, territory of runoff, and local flow characteristics between different coronary targets. Previous reports have supported the use of bilateral internal thoracic arteries to revascularize the left coronary circulation. If this becomes standardized practice, the optimal conduit for the right coronary system remains to be established. Proposed in the present article is a variant of bypass grafting of the RCA territory using a composite I-graft formed from the proximal portion of the right internal thoracic artery (ITA) in situ and the great saphenous vein (GSV) harvested by the «no-touch» technique. This technique is part of a CABG schematic algorithm worked out in our Clinic and called the «Penza Coronary Technology».

Key words: *coronary artery bypass grafting, intraoperative ultrasound Doppler flowmetry.*

INTRODUCTION

Coronary artery bypass grafting (CABG) remains an effective method of treatment for multivessel obstructive coronary disease with low rates of reintervention and excellent long-term survival and freedom from angina. Graft patency lies at the heart of its procedural success and durability, which in its turn largely depends on the appropriate choice of the conduit, as well as the target coronary artery (CA). Mention should be made that patency of one and the same conduit used for bypass grafting of the territory of either the left or right coronary artery (LCA and RCA, respectively) may differ, which is probably determined by differences in physiology, size, territory of runoff, and local flow characteristics between different coronary targets [1]. Thus, a number of studies demonstrated that optimal for the territory of the left coronary artery (LCA) is bimammary bypass grafting both «in situ» and as T- and Y-grafts [2–6]. However, in bypass grafting of the RCA and its branches, patency of the internal thoracic arteries (ITA) according to the literature data is lower as compared with that in bypass grafting of the LCA territory [7, 8]. The great saphenous vein (GSV) and radial artery as conduits for the RCA territory according to the literature data have comparable by patency remote results, but nonetheless are inferior to the ITA in bypass grafting of the LCA [1, 7, 8].

Hence, while the choice of conduits for the LCA system in order to ensure the best results is understood, the optimal conduit for the right coronary system remains to be established.

In the present work we propose a variant of bypass grafting of the RCA territory using a composite I-graft formed from the proximal portion of the right ITA in situ and the GSV harvested by the no-touch technique. This procedure is part of a CABG schematic algorithm developed in our Clinic and called the «Penza Coronary Technology».

Objectives. We aimed to describe a technique of bypass grafting of the RCA territory using a composite I-graft consisting of the proximal portion of the right ITA in situ and the GSV harvested by the «no-touch» technique, as well as to evaluate the immediate clinical and flowmetric results thus obtained.

PATIENTS AND METHODS

The study enrolled a total of 60 patients, with 44 (73%) males. The mean age of the overall cohort was 64 ± 7.7 years. All patients suffered from CAD and functional class III–IV angina of effort. The detailed clinical and demographic characteristics of the patients are shown in Table 1.

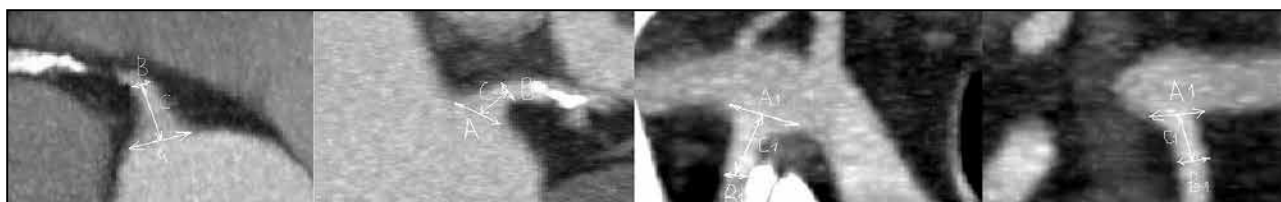

Fig. 1. Contrast-enhanced CT of the ostia of the left and right ITAs and CAs. A and A₁ – diameter of the ostium of the infundibular portion; B and B₁ – diameter of the tubular portion; C and C₁ – height of the infundibular portion of the CA and ITA, respectively

Table 1

Clinical and demographic characteristics of the patients		
Parameter	Value	95% CI (Q ₁ -Q ₃)
Age	64±8	62–66
Male gender, %	44 (73%)	61–83
BMI	30.2±3.2	2.6–4.2
FC III angina, %	38 (63%)	51–74
FC IV angina, %	22 (37%)	26–49
LV aneurysm, %	14 (23%)	14–35
LV EF, % <35%	8 (13%)	7–24
Multifocal atherosclerosis, %	4 (7%)	3–16
Diabetes mellitus, %	20 (33%)	23–46
COPD, %	11 (18%)	11–30
EuroSCORE, mean %	3.4±2.0	2.9–3.9

FC – functional class; CI – confidence interval; Q₁-Q₃ – interquartile range; EuroSCORE – European System for Cardiac Operative Risk Evaluation; BMI – body mass index; LV EF – left ventricular ejection fraction according to the Simpson's method; COPD – chronic obstructive pulmonary disease.

The preoperative examination included contrast-enhanced computed tomography (CT) of both ITAs and the ostia of the left and right coronary arteries, as well as Doppler ultrasonography of both ITAs. The CT findings were used to assess the following parameters: the diameter of the ostium of the infundibular portion of the ITAs and CAs, the diameter of their tubular portion, and height of the infundibular portion of the ITA and CA (Fig. 1).

Analysing these parameters, we draw a conclusion that the dimensions of the right ITA were equal to the corresponding dimensions of the right CA, with the same relationship revealed for the left ITA and CA. Thus, the coincidence of these dimensions allowed us to consider bypass grafting of the right CA territory with a graft of the right ITA and that of the left CA with a graft from the left ITA as anatomically substantiated.

PROCEDURE OF THE «PENZA CORONARY TECHNOLOGY»

The heart was accessed through a complete median sternotomy approach in all cases. The left and right ITAs were both harvested using

a skeletonization technique. The GSV was harvested with surrounding tissues according to the D. Souza's technique [9]. All visible lateral branches of the vein were ligated at a distance of about 0.5 cm from the venous wall with nonabsorbable polyfilament thread 3/0. Then the vein along with surrounding fat tissue was separated with the help of scissors. The distal and proximal portions of the thus exposed vein were not ligated and not cut off till the moment of formation of anastomoses, i. e., the vein was left in situ with neither opening of its lumen nor cannulation. To prevent kinking, the anterior surface of the vein was marked with dash lines by a felt-tipped pen; the vein was then covered with a napkin soaked with normal saline. Once the ITA was exposed, the pericardium was dissected. The RITA was cut off leaving a stump 3–4 cm long from the ostium. Then the GSV was cut off proximally and distally, with no cannulation, hydraulic dilation nor bougienage performed. The first stage consisted in formation of a composite I-graft between the autovein and RITA stump in an end-to-end fashion with 9/0 thread, the second stage was the formation of a T-graft: the end of the cut-off RITA to the side of the LITA with 9/0 thread (Fig. 2). Then we performed the conventional connection of the heart-lung machine (HLM), revision of the CA, and blood cardioplegia. We consecutively formed anastomoses first between the I-graft and RCA or its branches then between the limbs of the T-graft and branches of the circumflex artery and anterior descending artery. Blood flow along the grafts

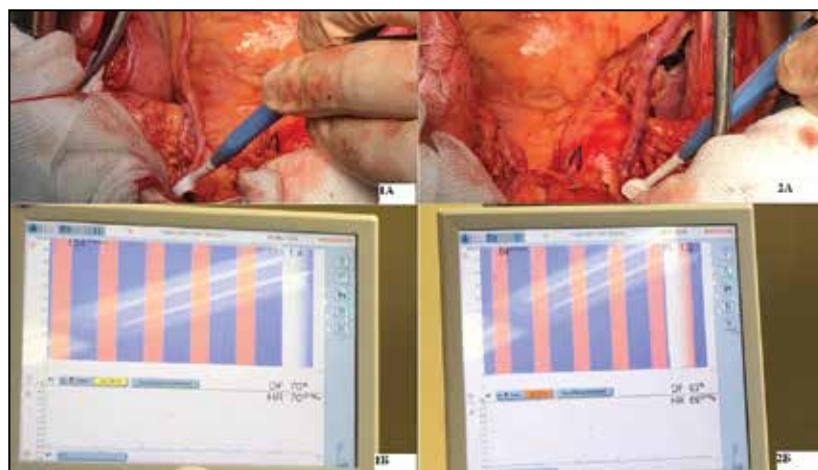


Fig. 2. Flowmetry (1B, 2B) of T-graft (1A), bypassing the territory of the left CA, and I-graft (2A), bypassing the right CA

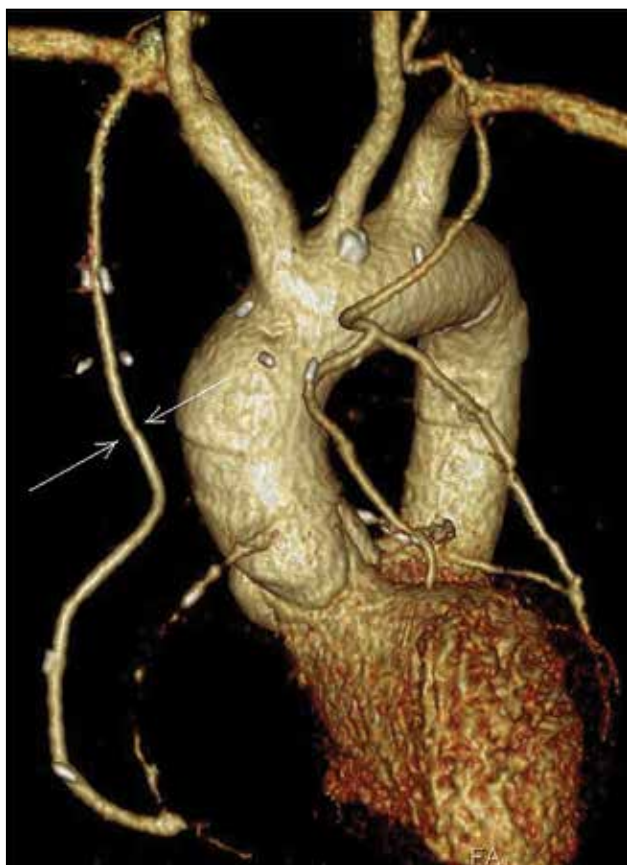

Fig. 3. Contrast-enhanced CT bypass angiography. Arrows indicate the end-to-end anastomosis of the vein and the stump of the right ITA

was assessed with the help of the VeriQ MediStim® flowmeter (Oslo, Norway) by the following parameters: volumetric velocity Q and resistance to blood flow – PI . The measurements were made during cardioplegic arrest after formation of each anastomosis at perfusion pressure of 45 mm Hg, after removing the clamp from the aorta, at the end of the operation immediately prior to bringing the sternal edges together at systemic pressure of 100–110 mm Hg [10, 11].

RESULTS

The average duration of the operation amounted to 288 ± 58 minutes, ECC time to 108 ± 47 min and that of myocardial ischaemia to 63 ± 29 min. The average length of stay in the intensive care unit (ICU) was 2 ± 0.6 days, the overall postoperative hospital stay averaged 12 ± 5 days, with the mean blood loss volume amounting to 340 ± 141 ml (Table 2).

The findings of flowmetry demonstrated that good parameters were achieved for blood flow along the I-graft for the RCA territory: in cross-clamped aorta – $Q = 64 \pm 12$ ml/min, $PI = 0.4 \pm 0.2$; on parallel ECC – $Q = 55 \pm 10$ ml/min, $PI = 1.1 \pm 0.4$; after the patients were weaned from extracorporeal circulation – $Q = 45 \pm 15$ ml/min, $PI = 1.9 \pm 0.6$ (Table 3).

Table 2
Parameters of intraoperative and postoperative periods

Parameters	$S \pm \sigma$	95% CI
Duration of the operation, min	288 ± 58	273–302
Duration of ECC, min	108 ± 47	95.8–120.1
Duration of MI, min	63 ± 29	55.5–70.4
Myocardial infarction	0	0
Stroke	0	0
Haemorrhage	0	0
Blood loss, ml	257 ± 141	220–293
Length of stay in ICU, days	2 ± 0.6	1.8–2.1
Overall postoperative hospital stay, days	12 ± 5	10.7–13.2

Note: ECC – extracorporeal circulation; MI – myocardial ischaemia, S – mean; $\pm \sigma$ – standard deviation; CI – confidence interval; ICU – intensive care unit.

Table 3
Parameters of the results of intraoperative flowmetry and Doppler ultrasonography after the operation for the graft of the right CA

Parameters (n=60)	$S \pm \sigma$	95% CI
Q in cross-clamped aorta, ml/min	64 ± 12	60.9–67
Q on the background of ECC, ml/min	55 ± 10	52.4–57.5
Q after the end of ECC, ml/min	45 ± 15	41.1–48.8
PI in cross-clamped aorta	0.4 ± 0.2	0.3–0.5
PI on the background of ECC	1.1 ± 0.4	1–1.2
PI after the end of ECC	1.9 ± 0.6	1.7–2.1
PSV, cm/s	70 ± 14	56–84
V_{vol} , ml/s	48.7 ± 13	35.5–61.9

Note: ECC – extracorporeal circulation; MI – myocardial ischaemia; CI – confidence interval, Q – volumetric velocity of blood flow along the graft; PI – index of resistance to blood flow along the graft; PSV – linear blood velocity along the ITA according to the findings of Doppler ultrasonography; V_{vol} – volumetric blood velocity according to the findings of Doppler ultrasonography.

In the postoperative period, in order to assess graft patency we performed contrast-enhanced CT bypass angiography (Fig. 3). No cases of graft failure were observed.

DISCUSSION

According to contemporary literature data, the results of bypass grafting of the RCA territory using various conduits are highly diverse and controversial. Previously it was reported that using T- and Y-grafts, when the RITA is used for bypass grafting of the RCA territory, was accompanied and followed by lower patency rates, with no advantages over other transplants used [1, 7]. This is explained by the possible presence of competitive blood flow in the native coronary artery, especially in the dominating right-type of blood supply of the heart, borderline stenosis and a large diameter of the coronary artery [7, 12]. Therefore, the T- and Y-configuration from the LITA and RCA cannot be the standard graft for all cases of CABG.

The great saphenous vein (GSV) still remains the most commonly used conduit, including for bypass grafting of the RCA territory. However, such disadvantages as a large diameter, structure of the wall, arterialization and development of atherosclerosis and unsatisfactory remote results associated therewith [13] resulted in renewed interest in the radial artery (RA). Some authors reported advantages of using the RA as a third arterial conduit for CABG by patency and long-term survival [14, 15]. Nevertheless, the RA is a muscle-type artery, prone to spasm, releasing less amounts of nitric oxide, which may result in competitive blood flow with the native CA, a decrease in blood flow, vasoconstriction and atrophy – the so-called string phenomenon [16]. The use of the RA is appropriate for bypass grafting of extended pronounced (> 90%) stenoses or occluded coronary arteries. Least suitable for bypass grafting with the radial artery are large-diameter ACs with local borderline stenoses. Thus, the radial artery is not a versatile conduit for the RCA territory.

The last decade has seen renewed interest to using the GSV for CABG. In order to prolong durability of autovenous grafts the following means have been suggested: storage solutions, gene therapy, external carcass-stents, use of an autovein for a composite graft, a no-touch vein harvesting technique [9].

K. Kim, et al. [17] carried out a randomized study wherein one group of patients underwent formation of a composite Y-graft from an autovein implanted to the side of the left ITA; group two patients were subjected to formation of a Y-graft from the right ITA anastomosed to the side of the left ITA. Patency of the autovein and right ITA at one year was comparable (96.9 and 97.9%, respectively). No statistically significant differences were found in the overall survival rates between the 2 groups at 1 and 4 years. Neither were statistically significant differences found between the 2 groups in the freedom from major adverse cardiovascular event rates. H. Hwang, et al. [18] reported similar 5-year results: patency of composite Y-grafts in the autovein group patients amounted to 94.1%, in the group of the right ITA – to 98.1%. Theoretical advantages of using an autovein from the ITA are considered by the authors to be as follows: continuous exposure to endothelium-protective substances such as nitric oxide released from the LITA, sufficient length of the autovein needed to reach all target CAs, as well as the fact that an autovein is exposed to less circulatory stress as compared with conduits implanted into the aorta. The same authors published the results of an ultrasonographic examination of a combined Y-graft at 1 year after operation [19]. The mean diameter of the SV conduit decreased during the first year postoperatively from 3.58 ± 0.61 mm to 2.71 ± 0.42 mm. The mean LD of the proximal left ITA increased from 2.41 ± 0.25 mm to 2.63 ± 0.30 mm.

The thickness of the intima-media complex did not differ between the LITA and the autovein.

In 2009, M. Cirillo, et al. described a technique of bypass grafting of the RCA territory in 18 patients with the help of a combined I-graft between an autovein and the proximal segment of the RITA, with the vein harvested classically. Of these, fourteen patients were also studied by computed tomographic angiography, demonstrating the patency of the new right composite conduit [20]. The findings of our previous study showed that an I-graft had better parameters of patency (95.5%) as compared with a T-graft (90%) and an autovein from the aorta (88.4%) after 3 years [21].

In 1996, D. Souza suggested a new «no-touch» technique of preparing the great saphenous vein for coronary artery bypass grafting surgery where the vein was harvested with a pedicle of surrounding tissue, which protected the vein from spasm therefore obviating the need for distension] [9]. In a series of studies, the author demonstrated a significantly higher patency of a «no-touch» autovein than the conventionally procured autovein [22, 23]. M. Dreifaltdt, et al. in their study showed superiority in the patency of the no-touch saphenous vein over that of the RA after 3 years in bypass grafting of the territory of both the right (92 vs 84%) and the left coronary arteries (97 vs 84%) [24]. The major benefits of the Souza's technique include: an atraumatic conduit-friendly approach, contributing to better preservation of endothelial integrity, intact adventitial layer with the functioning vasa vasorum, avoiding exposure of the venous intima to storage solutions, with the vein left in the circulation till the time of anastomosing [9]. The presence of surrounding tissues promotes easier deployment of the conduit in the cavity of the pericardium, as well as decreases probability of its kinking and bending.

An advantage of a composite graft over a conduit implanted into the aorta, on the one hand, and an advantage of a no-touch autovein over the classically procured vein, on the other hand, led to an idea of forming a composite I-graft from a no-touch autovein and the proximal portion of the RITA for bypass grafting of the RCA territory. The creation of a composite I-graft in its turn contributed to the development of a new technique of CABG, i. e. Penza Coronary Technology, which includes revascularization of the LCA territory with a Y- or T-graft and a composite I-graft for the RCA territory.

Excellent flowmetric and in-hospital results of the proposed technique provide reason enough to hope for long-term functioning of a composite I-graft and solution of the problem concerning the choice of an optimal conduit for the RCA. Thanks to using T- and Y-grafts for the LCA territory, this technique makes it possible to perform complete multiarterial myocardial revascularization.

CONCLUSIONS

1. The use of the vein from the right ITA decreases circulatory stress of the graft, owing to its sufficient length makes it feasible to perform revascularization of any segment of the RCA territory and solves the problem of choosing a conduit for the RCA territory in T-grafts

in the LCA territory.

2. The Penza Coronary Technology is a versatile reproducible technique making it possible to perform complete multiarterial myocardial revascularization.

Conflict of interest: none declared.

EDITORIAL COMMENT:

Coronary revascularization in CAD is intrinsically a conventional vascular operation which should be accompanied by cardioanaesthesiological support. That is why all principles developed in surgery of major arteries are applicable to coronary surgery:

a) any conduit functions better and longer (one of the main parameters of its assessment) if it is «intact» rather than composite (whereas the authors purposefully suggest to make it composite);

b) durability of any conduit undoubtedly depends on many factors. But one of the most important factors is that of preserving the integrity the distal bed of the artery subjected to bypass grafting. Today it is a postulate contested by no one. There even exist classifications of assessing the distal bed, such as predictors of bypass grafts functioning;

c) while forming anastomoses, the main technical problem is the creation of a distal anastomosis. BUT ACCORDING TO THE TECHNIQUE SUGGESTED BY THE AUTHORS THIS ANASTOMOSIS APPEARS TO BE IN NO WAY DIFFERENT FROM A CONVENTIONAL

AUTOVENOUS ANASTOMOSIS IN CORONARY ARTERY BYPASS GRAFTING, with all well-known drawbacks thereof;

d) the authors propose to form an additional anastomosis between the anterior thoracic artery and an autovein. It should be mentioned that this manipulation is technically challenging and belongs to the domain of microsurgery. That is why a «mass» surgical change over to this technique seems hardly possible, if at all;

e) mention should also be made of an obvious limitation of the study consisting in that the authors presented neither groups of comparison nor remote results. The thing is that the suggested SOPHISTICATION of the operation should be reasonably substantiated. And one of these reasons has to be evidence-based durability of the bypass graft suggested. If the proposed bypass graft proves to reliably function for more than 10 years and turns out to be superior by this parameter to the conventional autovenous bypass graft then it will be appropriate TO DISCUSS THE FEASIBILITY OF CHANGING OVER TO THE SUGGESTED TYPE OF CREATING A BYPASS GRAFT.

Meanwhile, this work may be interpreted as an initial, original, single-centre experience which should be localized in this Centre, waiting patiently until real 10-year results are obtained.

ЛИТЕРАТУРА/REFERENCES

1. **Hadinata I.E., Hayward P.A., Hare D.L., et al.** Choice of conduit for the right coronary system: 8-year analysis of Radial Artery Patency and Clinical Outcomes trial. *Ann. Thorac. Surg.* 2009 Nov; 88: 5: 1404–1409. doi: 10.1016/j.athoracsur.2009.06.010.
2. **Buttar S.N., Yan T.D., Taggart D.P., Tian D.H.** Long-term and short-term outcomes of using bilateral internal mammary artery grafting versus left internal mammary artery grafting: a meta-analysis. *Heart.* 2017 Sep; 103: 18: 1419–1426. doi: 10.1136/heartjnl-2016-310864. Epub 2017 Jun 23.
3. **Shi W.Y., Hayward P.A., Tatoulis J., et al.** Are all forms of total arterial revascularization equal? A comparison of single versus bilateral internal thoracic artery grafting strategies. *J. Thorac. Cardiovasc Surg.* 2015 Dec; 150: 6: 1526–1533, 1534.e1–3; discussion 1533–4. doi: 10.1016/j.jtcvs.2015.05.074. Epub 2015 Jul 2.
4. **Takagi H., Goto S.N., Watanabe T., et al.** A meta-analysis of adjusted hazard ratios from 20 observational studies of bilateral versus single internal thoracic artery coronary artery bypass grafting. *J. Thorac. Cardiovasc. Surg.* 2014 Oct; 148: 4: 1282–1290. doi: 10.1016/j.jtcvs.2014.01.010. Epub. 2014 Jan 16.
5. **Itagaki S., Cavallaro P., Adams D.H., Chikwe J.** Bilateral internal mammary artery grafts, mortality and morbidity: an analysis of 1 526 360 coronary bypass operations. *Heart.* 2013 Jun; 99: 12: 849–853. doi: 10.1136/heartjnl-2013-303672. Epub. 2013 Mar 20.
6. **Myocardial Revascularization Exclusively With Bilateral Internal Thoracic Arteries in T-Graft Configuration: Effects on Late Survival.** *Ann. Thorac. Surg.* 2016 May; 101:5: 1775–1781. doi: 10.1016/j.athoracsur.2015.10.074. Epub 2016 Jan 26.
7. **Gaudio M., Antoniadou C., Benedetto U., et al.** Mechanisms, Consequences, and Prevention of Coronary Graft Failure. *Circulation.* 2017 Oct 31; 136:18: 1749–

1764. doi: 10.1161/CIRCULATIONAHA.117.027597.
8. **Tatoulis J., Buxton B.F., Fuller J.A.** The right internal thoracic artery: the forgotten conduit—5,766 patients and 991 angiograms. *Ann. Thorac. Surg.* 2011; 92: 9–15. doi: 10.1016/j.athoracsur.2011.03.099.
 9. **Souza D.** A new no-touch preparation technique. *Scand. J. Thorac. Cardiovasc. Sur.* 1996; 30: 41–44.
 10. **Bazylev V.V., Nemchenko E.V., Karnakhin V.A., Pavlov A.A., Mikulyak A.I.** Flowmetric assessment of coronary bypass grafts in the conditions of artificial circulation and on the beating heart. *Angiology and Vascular Surgery.* 2016; 22: 1: 67–72 [in Russian].
 11. **Basylev V.V., Rosseikin E.V., Mikulyak A.I., Karpunkin O.A.** Ultrasonic Doppler flowmetry in intraoperative diagnosis of coronary bypass grafts incompetence. *Angiology and Vascular Surgery.* 2014; 20: 1: 25–50 [in Russian].
 12. **Tatoulis J., Buxton B.F., Fuller J.A.** The right internal thoracic artery: the forgotten conduit—5,766 patients and 991 angiograms. *Ann. Thorac. Surg.* 2011; 92: 9–15. doi: 10.1016/j.athoracsur.2011.03.099.
 13. **Fitzgibbon G.M., Kafka H.P., Leach A.J., et al.** Coronary bypass graft fate and patient outcome: angiographic follow-up of 5,065 grafts related to survival and reoperation in 1,388 patients during 25 years. *J. Am. Col. Cardiol.* 1996 Sep; 28:3: 616–626.
 14. **Taggart D.P., Altman D.G., Flather M.** ART (Arterial Revascularization Trial) Investigators. Associations Between Adding a Radial Artery Graft to Single and Bilateral Internal Thoracic Artery Grafts and Outcomes: Insights From the Arterial Revascularization Trial. *Circulation.* 2017 Aug 1; 136: 5: 454–463. doi: 10.1161/CIRCULATIONAHA.117.027659. Epub 2017 May 31.
 15. **Gaudino M., Puskas J.D., Di Franco A., et al.** Three Arterial Grafts Improve Late Survival: A Meta-Analysis of Propensity-Matched Studies. *Circulation.* 2017 Mar 14; 135:11: 1036–1044. doi: 10.1161/CIRCULATIONAHA.116.025453. Epub 2017 Jan 24.
 16. **Cao C., Manganas C., Horton M., et al.** Angiographic outcomes of radial artery versus saphenous vein in coronary artery bypass graft surgery: a meta-analysis of randomized controlled trials. *J. Thorac. Cardiovasc. Surg.* 2013 Aug; 146: 2: 255–261. doi: 10.1016/j.jtcvs.2012.07.014. Epub 2012 Aug 4.
 17. **Kim K.B., Hwang H.Y., Hahn S., et al.** A randomized comparison of the Saphenous Vein Versus Right Internal Thoracic Artery as a Y-Composite Graft (SAVE RITA) trial: One-year angiographic results and mid-term clinical outcomes. *J. Thorac. Cardiovasc. Surg.* 2014 Sep; 148: 3: 901–907; discussion 907–8. doi: 10.1016/j.jtcvs.2014.03.057. Epub. 2014 May 16.
 18. **Hwang H.Y., Lee K.H., Han J.W., Kim K.B.** Equivalency of Saphenous Vein and Arterial Composite Grafts: 5-Year Angiography and Midterm Clinical Follow-Up. *Ann. Thorac. Surg.* 2016 Aug; 102: 2: 580–588. doi: 10.1016/j.athoracsur.2016.02.017. Epub. 2016 May 19.
 19. **Hwang H.Y., Koo B.K., Oh S.J., Kim K.B.** Morphologic changes of the saphenous vein Y-composite graft based on the left internal thoracic artery: 1-year intravascular ultrasound study. *J. Thorac. Cardiovasc. Surg.* 2015 Feb; 49: 2: 487–493. doi: 10.1016/j.jtcvs.2014.08.056. Epub. 2014 Sep 16.
 20. **Cirillo M., Messina A., Dalla Tomba M., et al.** A New No-Touch Aorta Technique for Arterial-Source, Off-Pump Coronary Surgery. *Ann. Thorac. Surg.* 2009 Oct; 88: 4: e46–7. doi: 10.1016/j.athoracsur.2009.07.045.
 21. **Bazylev V.V., Nemchenko E.V., Pavlov A.A., Karnakhin V.A.** Indices of intraoperative flowmetry, determining patency of grafts in the remote period after revascularization of the right coronary artery. *Angiology and Vascular Surgery.* 2016; 22: 2: 60–66 [in Russian].
 22. **Souza D.S., Dashwood M.R., Tsui J.C., et al.** Improved Patency in Vein Grafts Harvested With Surrounding Tissue: Results of a Randomized Study Using Three Harvesting Techniques. *Ann. Thorac. Surg.* 2002 Apr; 73: 4: 1189–1195.
 23. **Samano N., Geijer H., Liden M., et al.** The no-touch saphenous vein for coronary artery bypass grafting maintains a patency, after 16 years, comparable to the left internal thoracic artery: A randomized trial. *J. Thorac. Cardiovasc. Surg.* 2015 Oct; 150: 4: 880–888. doi: 10.1016/j.jtcvs.2015.07.027. Epub. 2015 Jul 15.
 24. **Dreifaldt M., Mannion J.D., Bodin L., et al.** The No-Touch Saphenous Vein as the Preferred Second Conduit for Coronary Artery Bypass Grafting. *Ann. Thorac. Surg.* 2013 Jul; 96: 1: 105–111. doi: 10.1016/j.athoracsur.2013.01.102. Epub. 2013 May 16.

Адрес для корреспонденции:

Кобзев Е.Е.

Тел.: +7 (967) 440-19-05

E-mail: kobzev.evgeny.1983@yandex.ru

Correspondence to:

Kobzev E.E.

Tel.: +7 (967) 440-19-05

E-mail: kobzev.evgeny.1983@yandex.ru