

## **OUTCOMES OF THE ROSS PROCEDURE IN PATIENTS WITH AN ACCOMPANYING ASCENDING AORTIC ANEURYSM**

**KARASKOV A.M., BOGACHEV-PROKOFIEV A.V., SHARIFULIN R.M.,  
DEMINSKI I.I., ZHELEZNEV S.I., OPEN A.B., PIVKIN A.N.**

*Centre of Novel Surgical Technologies, Novosibirsk Scientific Research Institute of Circulatory Pathology named after Academician E.N. Meshalkin under the RF Ministry of Public Health, Novosibirsk, Russia*

*Analysed in the article are the results of the Ross procedure in patients presenting with dilatation of the ascending portion of the aorta.*

*A combination of aortic valve defects with dilatation of the ascending aorta of more than 45 mm supposes simultaneous prosthetic repair of the aortic valve and ascending aorta. The most common surgical procedure remains the Bentall–DeBono operation whose main disadvantage is associated with implantation of a mechanical prosthesis and the necessity of lifelong anticoagulant therapy. An alternative method is the Ross procedure demonstrating low risk of thromboembolic complications and freedom from anticoagulant therapy.*

*Over the period from 2002 to April 2015, specialists of the Novosibirsk Scientific Research Institute of Circulatory Pathology named after Academician E.N. Meshalkin carried out a total of 162 Ross procedures in patients presenting with accompanying dilatation of the ascending aorta (more than 45 mm). The mean diameter of the aorta at the level of Valsalva sinuses amounted to  $45.6 \pm 8.6$  mm, with that of the ascending aortic portion equalling  $53.4 \pm 7.8$  mm. The technique of total replacement of the aortic root was used in all cases. When the aneurysm extended to distal portions of the ascending aorta, additionally performed were the following procedures: in 24 patients – reduction aortoplasty, in 6 patients – replacement of the resected aorta with an insert from xenopericardium, and in 2 patients with a vascular graft.*

*The average duration of follow up amounted to  $40.1 \pm 21.6$  months. Ten patients were subjected to repeat operations for autograft dysfunction. There were no reoperations on the ascending portion of the aorta. The regression analysis revealed that predictors of the development of autograft dysfunction were the baseline dilatation of the fibrous ring (FR) of the aortic valve of more than 27 mm ( $p = 0.04$ ) and uncorrected arterial hypertension in the postoperative period ( $p = 0.03$ ). In the group of patients with the FR less than 27 mm there were no cases of allograft dysfunction.*

*The results of the study suggest that the Ross procedure is a safe and effective method in patients with accompanying dilatation of the ascending aorta. Risk factors for autograft dysfunction are dilatation of the FR of the aortic valve exceeding 27 mm and arterial hypertension in the postoperative period.*

**Key words:** *aortic valve defect, ascending aortic aneurysm, Ross procedure.*

### **INTRODUCTION**

Aortic valve defects in 15% of cases are combined with considerable dilatation of the ascending portion of the aorta [1, 2]. In people with the bicuspid aortic valve, dilatation of the ascending aorta may be noted in 40–80% [3]. According to the guidelines of the European Society of Cardiology, for patients who are going to undergo interventions on the aortic valve with the aortic diameter of exceeding 45 mm there should be considered a possibility of simultaneous prosthetic repair of the ascending aorta [4]. However, the recommendations have no clear-cut indications which method should be preferred in a particular case. The most commonly used method is the Bentall–DeBono procedure, its main disadvantage is associated with implantation of a mechanical graft and consequently with the necessity of lifelong anticoagulant therapy.

Alternative technologies include prosthetic repair of the aortic valve with an allograft and pulmonary autograft (Ross procedure), in which the risk of thromboembolic complications is low, therefore anticoagulation therapy may be discontinued. The use of allografts in an aneurysm of the aortic root due to high incidence of their structural degeneration is indicated for aged patients [5, 6]. A pulmonary autograft in the aortic position possesses a longer life service; however, application of the method in an accompanying aneurysm of the ascending aorta is limited to single cardiosurgical centres with contradictory results [7]. By now, specialists of the Novosibirsk Scientific Research Institute of Circulatory Pathology named after Academician E.N. Meshalkin have gained large experience with the Ross procedure [8–12], including in this cohort of patients. The present work was aimed at both assessing the results of the Ross procedure

**Karaskov A.M., et al. Outcomes of the Ross procedure  
in patients with an accompanying ascending aortic aneurysm**

Preoperative characteristics of patients		
Parameter	Number, n	%
Gender		
Male	134	82,7
Female	28	17,3
Etiology		
Bicuspid aortic valve	79	48,8
CRHD	43	26,5
Infective endocarditis	12	7,4
Degenerative defect	12	7,4
Prosthetic dysfunction	2	1,2
Connective tissue dysplasia	14	8,6
Haemodynamic variant		
Stenosis	65	40,1
Insufficiency	74	45,7
Combined defect	21	13,0
Prosthetic dysfunction	2	1,2
Prior operations		
Prosthetic repair of the aortic valve	3	1,85
Balloon valvulodilatation of the AV	1	0,6
Resection of aortic coarctation	1	0,6
PTCA	2	1,2
FC HF (according to the NYHA classification)		
I	7	4,3
II	55	34,0
III	95	58,6
IV	5	3,1
Left ventricular ejection fraction		
≥ 50%	137	84,6
< 50%	25	15,4

*Note: CRHD – chronic rheumatic heart disease; AV – aortic valve; FC HF – functional class of heart failure; PTCA – percutaneous transluminal coronary angioplasty.*

in patients with dilatation of the ascending aorta and analysing the predictors of unsatisfactory outcomes.

### MATERIALS AND METHODS

Over the period from 2002 to April 2015 specialists of the Novosibirsk Scientific Research Institute of Circulatory Pathology named after Academician E.N. Meshalkin performed a total of 756 Ross procedures in adult patients over 16 years old. We carried out a retrospective analysis of the results of correction in 162 patients with accompanying dilatation of the root ascending aorta ( $\geq 45$  mm). The mean age amounted to  $51.0 \pm 10.7$  years. General characteristics of the patients are shown in Table 1.

#### Surgical technologies

In all cases the Ross procedure was performed by means of the total root replacement technique with reimplantation of the coronary arteries ostia into the autograft (Table 2).

A peculiarity of exposing a pulmonary autograft in patients with an aortic aneurysm consists in the necessity of obtaining an autograft of an optimal length sufficient for maximally possible replacement of the altered ascending aorta. For this purpose, the pulmonary artery was cut immediately in front of the bifurcation. If the aneurysm

Intraoperative data		
Parameter	Value	Number, n (%)
Duration of artificial circulation, min	183.5±30.1	
Aortic occlusion time, min	138.9±23.9	
Cardioplegia:		
Custodial cardioplegia		158 (97,5)
Blood cardioplegia		4 (2,5)
Method of autograft implantation:		
Uninterrupted suture		158 (97,5)
Separate U-shaped sutures		4 (2,5)
Interventions on the aorta:		
Replacement of the aneurysm with a pulmonary autograft		130 (80,2)
Reduction aortoplasty according to Robicsek		24 (14,8)
Prosthetic repair of the ascending aorta with a xenograft		6 (3,7)
Prosthetic repair of the aorta with a vascular graft		2 (1,2)
Prosthetic repair of the aortic arch		1 (0,6)
Baseline dilatation of the FR of the aortic valve ( $\geq 27$ mm)		101 (62,3)
Reduction of the FR		30 (18,5)
Exoprosthetic repair of the autograft		3 (1,85)
Accompanying interventions		
Aortocoronary bypass grafting		12 (7,4)
Mitral valve plasty		9 (5,6)
Tricuspid valve plasty		8 (4,9)
Radiofrequency fragmentation of the atria		8 (4,9)
Closure of IVSD/IASD		4 (2,5)
Ross–Konno operation		2 (1,2)
Reconstruction of the RVOT		
Pulmonary homograft		38 (23,5)
Epoxy-treated xenoconduits		105 (64,8)
Glutaraldehyde-treated xenoconduits		17 (10,5)
PTFE conduit		1 (0,6)
RVOT conduit mean diameter, mm	26,7±1,1	

*Note: FR – fibrous ring of the aortic valve; IVSD – interventricular septum defect; IASD – interatrial septum defect; RVOT – right ventricular outlet tract; PTFE – polytetrafluoroethylene.*

was located either at the level of the root or proximal third of the ascending aorta we simultaneously replaced the affected aortic valve and resected portion of the aorta with the pulmonary complex (130 patients). If the aneurysm extended to distal portions of the ascending aorta, when the length of the autograft was insufficient, we performed reduction plasty of the dilated distal portion of the ascending aorta (24 patients) (Fig. 1), or used an insert between the autograft and aorta from the xenopericardium (6 patients) or a vascular prosthesis (2 patients) (Fig. 2). In a wide fibrous ring of the aortic valve (more than 27 mm) and non-conformance of the diameters of the rings of the pulmonary and aortic valves exceeding 2 mm, we performed its reduction. We used such manipulations as plication of the fibrous ring by separate U-shaped sutures (Fig. 3) or reduction with the mattress suture along the perimeter of the fibrous ring with tying on the bougie of the corresponding diameter (Fig. 4). In three cases we carried out exoprosthetic repair of the autograft (Fig. 5).

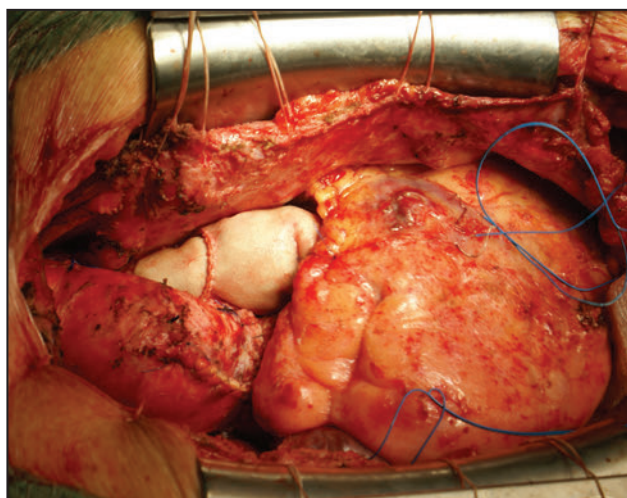


Fig. 1. Reduction aortoplasty of the ascending aortic portion.

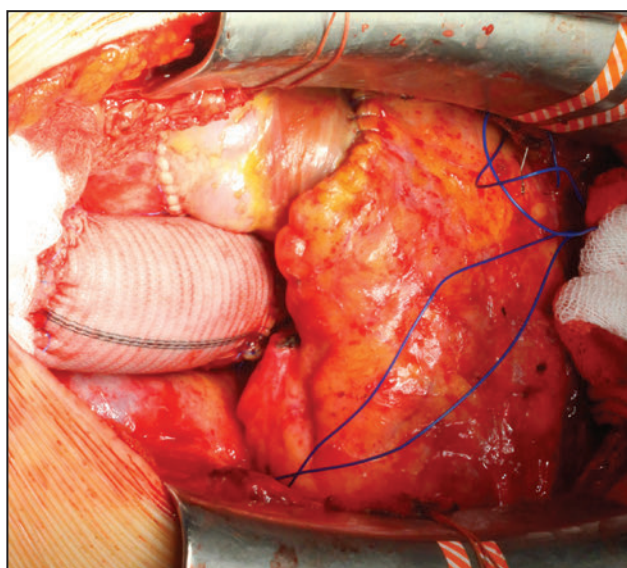


Fig. 2. Prosthetic repair of the ascending aorta distal to the pulmonary autograft by an insert from the vascular graft.

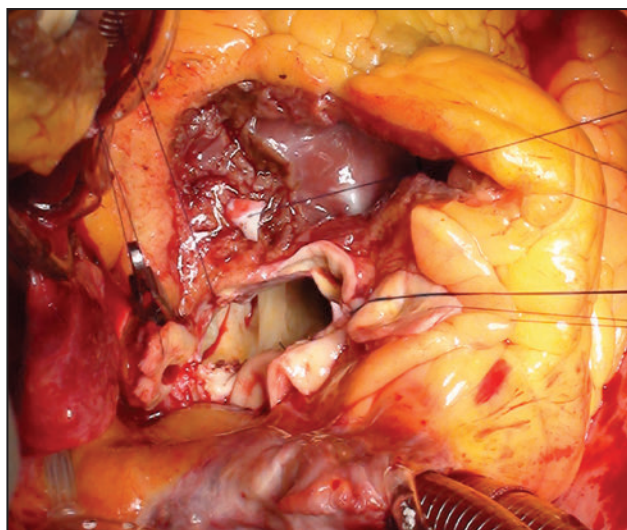


Fig. 3. Reduction of the aortic valve fibrous ring by means of separate U-shaped sutures.

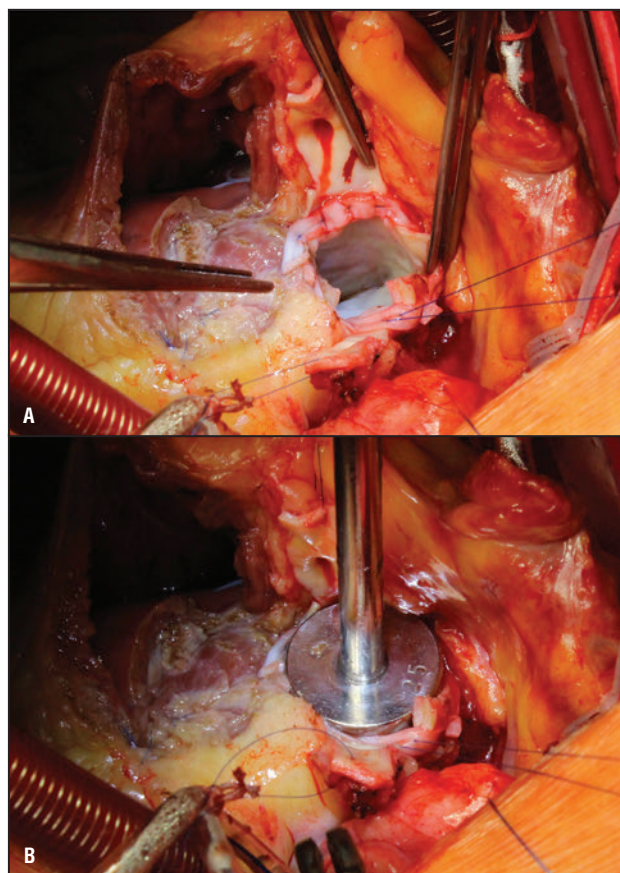


Fig. 4. Reduction of the aortic valve fibrous ring by means of an interrupted suture: a) fibrous ring after reduction by the uninterrupted mattress suture with the use of xenopericardium strips (the suture is pulled outward in the projection of the noncoronary sinus); b) fibrous ring is reduced with a reinforcing suture on a 25-mm bougie.

#### Assessment of autograft function

All patients after cutting off artificial circulation were intraoperatively subjected to transesophageal EchoCG in order to assess haemodynamics on the neo-aortic valve. It was followed by control transthoracic ultrasound examination prior to discharge and at annual examination. After discharge, we examined a total of 132 (81.5%) patients. The average duration of follow up amounted to  $40.1 \pm 21.6$  months.

#### Statistical analysis of data

The obtained findings were assessed by means of the Statistica 6.0 package. The results are represented as the mean and standard deviation ( $M \pm \sigma$ ). The actuarial freedom from secondary operations/dysfunction of the autograft was calculated according to the Kaplan–Mayer technique. We also analysed risk factors for the development of autograft insufficiency (aortic insufficiency above moderate) and dilatation of the autograft (diameter  $\geq 40$  mm) in the postoperative period. The first stage consisted in correlation analysis using the gamma-coefficient. The factors having significant correlation or closer to that ( $p < 0.01$ ) were included

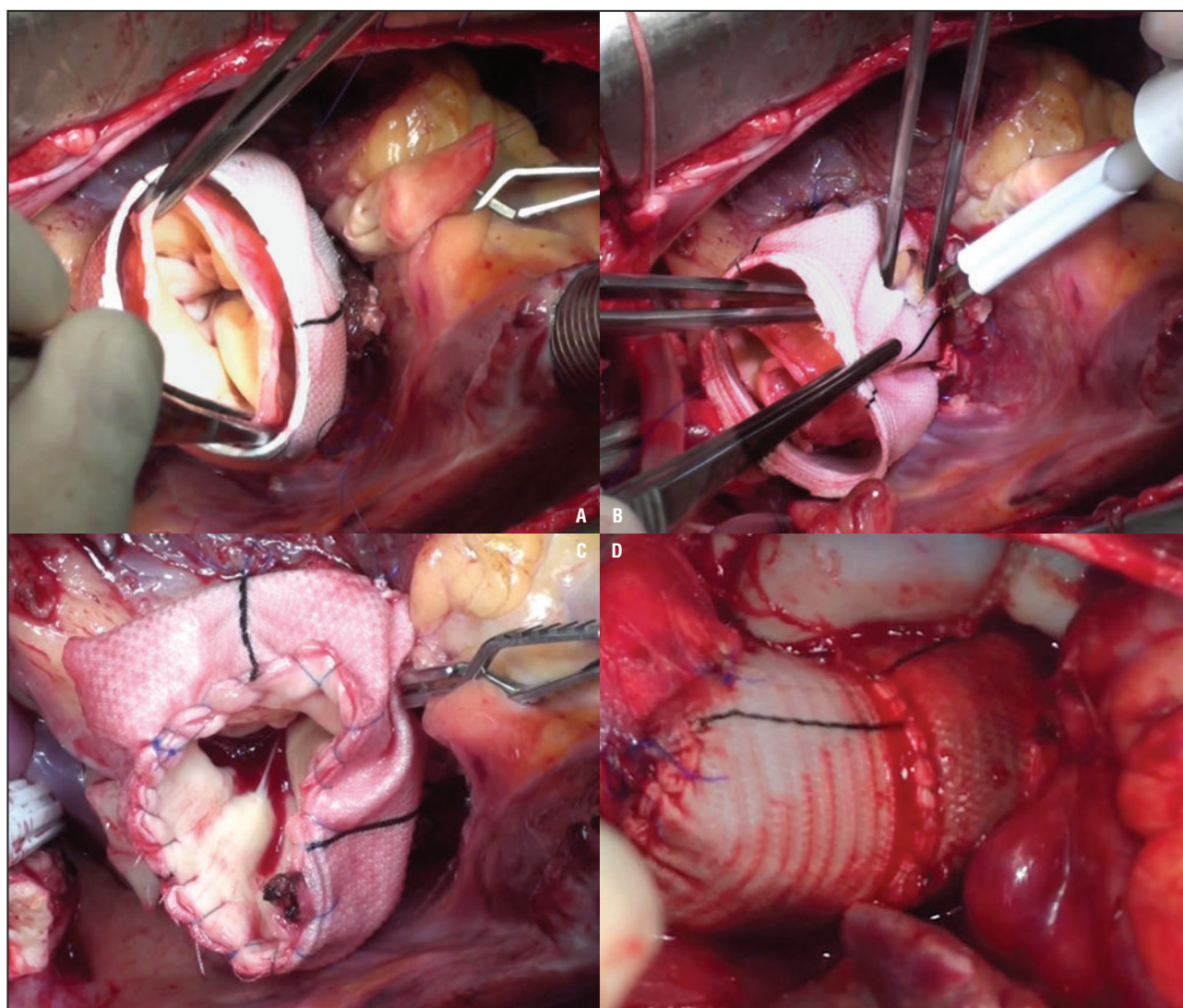


Fig. 5. Exoprosthesis repair of the autograft with a vascular prosthesis: a) pulmonary autograft is placed into the vascular prosthesis; b) formation of holes in the vascular graft for ostia of coronary arteries; c) a distal line of sutures between the autograft and vascular prosthesis is formed; d) final view of the operation. The dilated portion of the aorta distal to the autograft is replaced with an insert from the vascular prosthesis.

into the regression model. Differences at  $p < 0.05$  were regarded as statistically significant.

### RESULTS

Hospital lethality amounted to 5.6%. In the early postoperative period pronounced aortic insufficiency was revealed in 3 (1.9%) patients, all of whom underwent secondary prosthetic replacement of the aortic valve with a mechanical prosthesis. At discharge, moderate aortic insufficiency was observed in 3 patients. In the remaining cases, regurgitation on the autograft was not observed, or was insignificant.

One lethal outcome was observed in the remote period, with the cause of death being ischaemic stroke.

Indications for repeat interventions were considered to be pronounced aortic insufficiency, aneurysm of the autograft/ascending portion of the aorta (diameter  $\geq 55$  mm), and false aneurysms. Reoperations on the autograft

were carried out in 7 (5.3%) patients with pronounced aortic insufficiency, who undergone secondary repeat prosthetic repair replacement of the aortic valve with a mechanical prosthesis. The mean time from the Ross procedure to reoperations amounted to  $19 \pm 9.4$  months. In six cases autograft dysfunction was caused by FR dilatation, in one case — infective endocarditis. There were no secondary operations on the ascending aorta, however 2 patients were found to have dilation up to 5.0 cm, with no haemodynamic changes on the neo-aortic valve.

The actuarial freedom from reoperation on the autograft 5 years after amounted to  $89.0 \pm 6.6\%$  (Fig. 6). There were no lethal outcomes in secondary operations.

The correlation analysis revealed that the development of autograft insufficiency was influenced by the initial baseline dilatation of the FR of the aortic valve and uncorrected arterial hypertension (AH) in the postoperative period (Table 3). The regression model

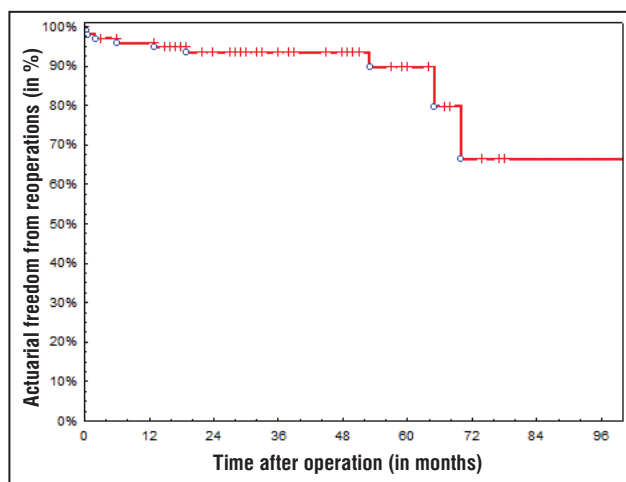


Fig. 6. Actuarial freedom from reoperations on the autograft.

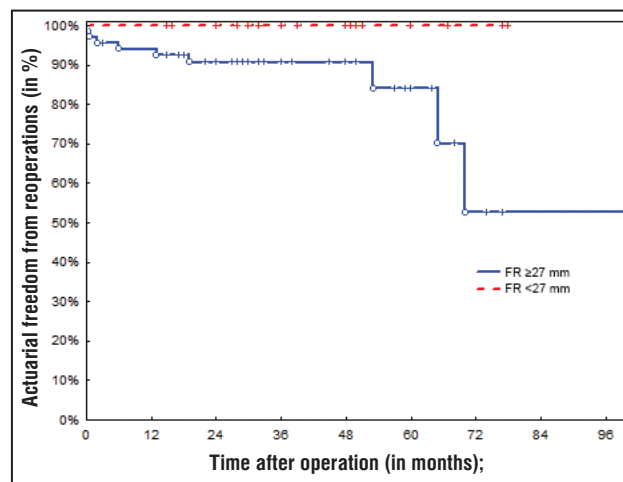


Fig. 7. Comparison of actuarial freedoms from reoperations on the autograft depending on the diameter of the fibrous ring of the aortic valve: on the axis of ordinate (y) – actuarial freedom from reoperations (in %); on the axis of abscissa (x) – time after operation (in months); red dotted line – freedom from reoperations with the diameter of the FR of the aortic valve <27 mm; blue solid line – freedom from reoperations with the diameter of the FR of the aortic valve ≥27 mm.

showed that dilatation of the FR and arterial hypertension were also independent predictors for the development of autograft dysfunction in the remote period.

In the group of patients with initially dilated FR, the 5-year actuarial freedom from reoperations on the autograft amounted to  $71.1 \pm 10.3\%$ , whereas in the group of patients with FR less than 27 mm there were no reoperations (Fig. 7).

Assessing efficacy of FR reduction revealed no significant influence thereof on progression of aortic regurgitation ( $p=0.08$ ).

Aortic insufficiency of  $\geq 2$  degree in the early postoperative period was not a statistically significant factor, which may be explained by a small number of patients ( $n=3$ ) with moderate regurgitation at the time of discharge.

The findings of postoperative ultrasound examination and MSCT showed no significant increase in the aortic dimensions at all levels as compared with the data at discharge (Table 4).

The correlation analysis revealed relationship between uncorrected arterial hypertension and dilatation of the autograft ascending aorta in the postoperative period, however the multivariate analysis revealed no statistically significant influence of the analysed factors on the development of dilation of the autograft (Table 5).

## DISCUSSION

In aortic valve defects combined with an ascending aortic aneurysm the most frequently used procedure is either the Bentall–DeBono procedure or separate prosthetic repair of the aortic valve and ascending aorta. Disadvantages of these methods are associated with implantation of a mechanical prosthesis: necessity of life-long anticoagulant therapy, high risk for the development of thromboembolic complications and haemorrhage [13, 14]. Besides, prosthetic replacement of the aortic valve with a mechanical prosthesis is associated with a relatively high risk of prosthetic endocarditis associated with elevated mortality [15]. In some patients negative influence on quality of life may be exerted by the sound of the working closing element of the valve [16].

The Ross procedure is an alternative to the conventional methods of prosthetic repair of the aortic valve. Using a pulmonary autograft in the aortic position makes it possible to obtain excellent haemodynamic

Parameter	Univariate analysis		Multivariate analysis	
	Gamma	p	OR	p
Gender	0.16	0.08	0.26	0.14
Aortic insufficiency	0.05	0.76	–	–
Bicuspid aortic valve	-0.1	0.46	-	-
FR dilatation ( $\geq 27$ mm)	0.55	0.0007	5.2	0.04
Aortic aneurysm aetiology (connective tissue dysplasia)	0.33	0.2	-	-
Nature of intervention on the aorta	0.13	0.39	-	-
Active infective endocarditis (before/after the operation)	-0.03	0.93	-	-
AOI of $\geq 2$ degree in the early postoperative period	0.14	0.48	-	-
Postoperative arterial hypertension	0.87	<0.0001	3.6	0.03

Note: Gamma – correlation coefficient, OR – odds ratio, AOI – aortic insufficiency.

**Karaskov A.M., et al. Outcomes of the Ross procedure  
in patients with an accompanying ascending aortic aneurysm**

<b>Dynamics of aortic dimensions after operation</b>								Table 4
	Prior to operation	At discharge	After 12 months	After 24 months	After 36 months	After 48 months	After 60 months	
FR, mm	26.4 ±2.8	25.1±1.6	25.4±1.8*	25.6±1.6*	25.6±1.7*	25.8±1.9*	25.7±1.9*	
Sinuses, mm	45.6±8.6	33.7±3.8	34.1±4.3*	35.3±4.5*	35.6±4.3*	36.3±5.3*	37.8±5.8*	
Ascending portion, mm	53.4±7.8	34.8±4.6	35.7±4.9*	36.1±4.6*	36.3±3.7*	37.5±4.7*	38.9±5.7*	

Note: \*  $p > 0.05$  (compared with the parameters at discharge).

<b>Analysis of predictors for the development of autograft dilatation in the postoperative period</b>					Table 5
Parameter	Univariate analysis		Multivariate analysis		
	Gamma	p	Odds ratio	p	
Gender	-0.1	0.5	-	-	
Aortic insufficiency	0.14	0.38	-	-	
Bicuspid aortic valve	0.23	0.1	0.7	0.26	
FR dilation ( $\geq 27$ mm)	-0.03	0.84	-	-	
Connective tissue dysplasia	0.25	0.28	-	-	
Character of intervention on the aorta	0.22	0.2	-	-	
Active infective endocarditis (before and after operation)	0.16	0.15	-	-	
AOI of $\geq 2$ degree in the early postoperative period	0.13	0.18	-	-	
Postoperative AH	0.34	0.03	0.5	0.14	

We had shown earlier that the presence of an aneurysm of the ascending aorta did not increase the risk of re-operation [12]. Using a pulmonary autograft makes it possible to effectively remove the dilated portion of the aorta, with the majority of patients not developing meaningful dilatation of the autograft ascending aorta in the mid-remote period after the operation.

According to the literature data the main cause of the

development of autograft dysfunction is dilatation of the neo-aortic root (primarily at the level of the fibrous ring and sinotubular junction), leading to loss of coaptation of valvular leaflets and the appearance of regurgitation [23, 28]. The most significant risk factors for the development of insufficiency of a neo-aortic valve are as follows: baseline aortic insufficiency [17, 18, 23, 28–30], dilatation of the aortic valve FR [17, 18]; the total root replacement technique [31]; bicuspid aortic valve [32]; young age [33]; male gender [18]; arterial hypertension [22, 27, 33].

results, which makes it possible to refuse anticoagulant therapy, as well as to carry out lead an active way of life style [17, 18]. According to the literature data, a pulmonary autograft is superior to mechanical prostheses by haemodynamic characteristics [19, 20], whereas and while the frequency of the development of thromboembolic complications and haemorrhage following after the Ross procedure is less [21]. It was also demonstrated that remote survival after the Ross procedure is superior to that of using mechanical prostheses and allografts and comparable to survival in the general population [22–24]. However, some a series of authors explain advantages in the remote survival rate by a more careful selection of patients for the operation [21]. On the other hand, optimization of anticoagulant therapy in implantation of mechanical prostheses in the aortic position makes it possible to decrease the risk of complications and to increase survival [25].

In our study the main cause of dysfunctions was also dilatation of the autograft FR. Independent predictors of the development of aortic insufficiency in the postoperative period turned out to be a wide FR ( $\geq 27$  mm) and uncorrected arterial hypertension. The initial aortic insufficiency and bicuspid aortic valve, if not combined with FR dilation, did not increase the risk for autograft dysfunction. We consider that a wide FR should compulsorily be reduced and reinforced. Some authors reported efficacy of reducing methodics [18, 27]. However, there also exists a controversial point of view. According to T. David, et al., reduction of the FR does not prevent the development of autograft dysfunction since a wide RF is an indirect sign of connective tissue dysplasia [17]. We did not reveal significant effect of FR reduction on progression of aortic insufficiency in the postoperative period, which can probably be explained by a short term of follow up in this subgroup of patients.

It is known that adaptation of physical properties of a pulmonary autograft to systemic haemodynamics

R. Elkins, et al. showed safety and efficacy of prosthetic replacement of the aortic valve with a pulmonary autograft in patients with an aortic aneurysm. The authors suggested in dilation of the aorta to additionally carry out reduction aortoplasty, in aneurysm – prosthetic repair of the ascending aorta with a vascular graft [2, 26]. It was also shown that the use of a vascular graft has a stabilizing effect on the sinotubular junction, preventing autograft dilatation in the remote period [18, 27].

According to some authors, the Ross procedure despite advantages did not find wide application in presence of an accompanying aneurysm of the ascending aorta, since such patients are running high risk for the development of autograft dysfunction in the remote period [7].

occurs in early postoperative terms [34]. Therefore, correction of arterial hypertension may prevent early dilation and dysfunction of the autograft. We attach great importance to the protocol of strict antihypertensive therapy, especially during the first 6 months after the Ross operation procedure.

In order to prevent autograft dilatation, especially in high-risk patients, various methods of reinforcing the autograft have been proposed. The most commonly frequently used is external fixation of the FR and sinotubular crest with teflon strips or pericardium, stabilization of the sinotubular crest with a vascular graft. In the literature there is description a method of reinforcing the neoroot by means of inserting a pulmonary autograft into the vascular prosthesis [35], but in doing so a series of the autograft's physiological properties are lost. We used this technique technology in 3 patients, however small experience does not allow us to evaluate its efficacy in the remote period.

Using a pulmonary autograft for replacing the aortic valve and ascending aorta is contraindicated in pathology of the mitral valve, requiring its prosthetic repair, in anomalies of the pulmonary artery valve, pronounced systolic dysfunction of the left ventricle, multiple-vessel lesion of the coronary bed [36]. The most prevailing opinion is that the Ross procedure is appropriate feasible only in young patients [17]. However, there are studies suggesting safety and efficacy of this method in patients over 60 years [37]. In our opinion, the age should not be a determining factor while deciding upon a possibility of carrying out the Ross procedure. An individual approach is required with due regard for the patient's wishes, anatomical peculiarities, and accompanying diseases. However, at the age over 65 years preference should be given to biografts and allografts. According to the opinion of most authors, connective tissue dysplasia (Marfan syndrome and others) is an absolute contraindication to using a pulmonary autograft [36], although there are sporadic reports regarding successful use of the modified Ross procedure (with encasing of the autograft into the vascular prosthesis) in such patients [38]. We also have experience in carrying out the Ross procedure in 14 patients with connective tissue dysplasia (of these, 3 patients with confirmed Marfan syndrome) with good immediate results. Taking into consideration a short term of follow up ( $20.7 \pm 3.1$  months) we currently cannot speak in the affirmative of feasibility of carrying out the Ross procedure in this cohort of patients.

Indications for reoperation in patients with autograft dilatation with no significant aortic regurgitation remain disputable [18, 39]. Considering the literature-described cases of dissection of the dilated autograft [40], it is probable that policy in such situations should be more active. When determining indications for reoperation, we are guided by the recommendations of the European

Society of Cardiology [4]. An indication for secondary reconstructive interventions on the ascending aorta with no aortic insufficiency we consider to be the diameter at the level of the autograft/ascending aorta to be more than 55 mm, with a diameter of 50 mm requiring dynamic follow up with assessment of aortic dimensions twice a year. Accretion of the aortic diameter by 3 mm and more per year surgical treatment is also indicated.

In our series, all patients with autograft dysfunction were subjected to secondary replacement of the aortic valve with a mechanical prosthesis. However, according to some publications this cohort of patients may successfully be treated by valve-sparing methods (David and Yacoub) with comparable results of valve-sparing operations for treating aneurysms of the native aorta [27, 41, 42].

## CONCLUSION

The results of the study demonstrate that the Ross procedure is safe and effective in patients with ascending aortic aneurysm. A principal technological aspect of the operation is exposure of an optimal-length pulmonary complex for total replacement of the aneurysmatically altered portion of the ascending aorta. In insufficient length, thinned wall of the autograft it is necessary to use synthetic (biological) materials for replacement of the ascending aorta. In the postoperative period there is no significant increase in aortic dimensions at all levels as compared with the findings at discharge. The main predictor for the development of autograft dysfunction is dilatation of the FR of the aortic valve of more than 27 mm, thus requiring reduction of the ring in combination with its reinforcement. Not a less important risk factor is arterial hypertension, thus suggesting necessity of strict compliance with antihypertensive therapy in the postoperative period.

## ЛИТЕРАТУРА/REFERENCES

1. *Leyh R.G., Hagl C., Kofidis T., Haverich A.* Impact of ascending aorta replacement combined with a Ross procedure on autograft root distensibility and function in patients with combined pathology of the aortic valve and ascending aorta. *Interact. Cardiovasc. Thorac. Surg.* 2003; 2: 116–119.
2. *Elkins R.C., Lane M.M., McCue C.* Ross procedure for ascending aortic replacement. *Ann. Thorac. Surg.* 1999; 67: 1843–1845.
3. *Michelen H.I., Desjardins V.A., Avierinos J.F., et al.* Natural history of asymptomatic patients with normally functioning or minimally dysfunctional bicuspid aortic valve in the community. *Circulation.* 2008; 117: 2776–2784.
4. *Erbel R., Aboyans V., Boileau C., et al.* 2014 ESC Guidelines on the diagnosis and treatment of aortic diseases. *Eur. Heart J.* 2014; 35: 2873–2926.

5. **Takkenberg J.J., Klieverik L.M., Bekkers J.A., et al.** Allografts for aortic valve or root replacement: insights from an 18-year single-center prospective follow-up study. *Eur. J. Cardiothorac. Surg.* 2007; 31: 851–859.
6. **O'Brien M.F., Harrocks S., Stafford E.G., et al.** The homograft aortic valve: a 29-year, 99.3% follow up of 1,022 valve replacements. *J. Heart Valve Dis.* 2001; 10(3): 334–344.
7. **Luciani G.B., Favaro A., Casali G., et al.** Ross operation in the young: a ten-year experience. *Ann. Thorac. Surg.* 2005; 80: 2271–2277.
8. **Litasova E.E., Nazarov V.M., Zheleznev S.I., et al.** First experience with the Ross procedure as repeat valve correction. *Pathology of Circulation* 2009; 4: 9–13 (in Russian).
9. **Karaskov A.M., Zheleznev S.I., Bogachev A.B., et al.** Ross procedure as a stage of combined intervention for combined pathology of the heart. *Cardiology and Cardiovascular Surgery.* 2010; 3: 64–67 (in Russian).
10. **Karaskov A.M., Zheleznev S.I., Bogachev A.B., et al.** Ross procedure in patients with pronounced left-ventricular systolic dysfunction. *Pathology of Circulation.* 2013; 1: 5–11 (in Russian).
11. **Karaskov A.M., Demin I.I., Sharifulin R.M., et al.** Various types of conduits for reconstruction of outflow pathways from the right ventricle in adults undergoing Ross procedure: comparative analysis. *Pathology of Circulation.* 2013; 2: 23–27 (in Russian).
12. **Karaskov A.M., Demin I.I., Sharifulin R.M., et al.** Risk factors for the development of pulmonary autograft dysfunction after the Ross procedure. *Cardiology and Cardiovascular Surgery.* 2015; 2: 54–68 (in Russian).
13. **Vink R., Kraaijenhagen R.A., Hutten B.A., et al.** The optimal intensity of vitamin k antagonists in patients with mechanical heart valves: a meta-analysis. *J. Am. Coll. Cardiol.* 2003; 42: 2042–2048.
14. **Takkenberg J.J., Puvimanasinghe J.P., van Herwerden L.A.** Optimal target international normalized ratio for patients with mechanical heart valves. *J. Am. Coll. Cardiol.* 2004; 44: 1142–1143.
15. **Vongpatanasin W., Hillis L.D., Lange R.A.** Prosthetic heart valves. *N. Engl. J.* 1996; 335: 407–416.
16. **Blome-Eberwein S.A., Mrowinski D., Hofmeister J., Hetzer R.** Impact of mechanical heart valve prosthesis sound on patients' quality of life. *Ann. Thorac. Surg.* 1996; 61: 594–602.
17. **David T.E., David C., Woo A., et al.** The Ross procedure: outcomes at 20 years. *J. Thorac. Cardiovasc. Surg.* 2014; 147: 85–94.
18. **Elkins R.C., Thompson D.M., Lane M.M., et al.** Ross operation: 16-year experience. *J. Thorac. Cardiovasc. Surg.* 2008; 136: 623–630.
19. **Porter G.F., Skillington P.D., Bjorksten A.R., et al.** Exercise hemodynamic performance of the pulmonary autograft following the Ross procedure. *J. Heart Valve Dis.* 1999; 8: 516–521.
20. **Doss M., Wood J.P., Kiessling A.H., Moritz A.** Comparative evaluation of left ventricular mass regression after aortic valve replacement: a prospective randomized analysis. *J. Cardiothorac. Surg.* 2011; 6: 136.
21. **Klieverik L.M., Noorlander M., Takkenberg J.J., et al.** Outcome after aortic valve replacement in young adults: is patient profile more important than prosthesis type? *J. Heart Valve Dis.* 2006; 15(4): 479–487.
22. **El-Hamamsy I., Eryigit Z., Stevens L.M., et al.** Long-term outcomes after autograft versus homograft aortic root replacement in adults with aortic valve disease: a randomised controlled trial. *Lancet.* 2010; 376: 524–531.
23. **Mokhles M.M., Rizopoulos D., Andrinopoulou E.R., et al.** Autograft and pulmonary allograft performance in the second post-operative decade after the Ross procedure: insights from the Rotterdam Prospective Cohort Study. *Eur. Heart J.* 2012; 33: 2213–2224.
24. **Andreas M., Wiedemann D., Seebacher G., et al.** The Ross procedure offers excellent survival compared with mechanical aortic valve replacement in a real-world setting. *Eur. J. Cardiothorac. Surg.* 2014; 46(3): 409–413.
25. **Mokhles M.M., Körte H., Stierle U., et al.** Survival comparison of the Ross procedure and mechanical valve replacement with optimal self-management anticoagulation therapy propensity-matched cohort study. *Circulation.* 2011; 123: 31–38.
26. **Elkins R.C.** The Ross operation in patients with dilation of the aortic annulus and of the ascending aorta. *Oper. Tech. Cardiac Thorac. Surg.* 1997; 12: 331–341.
27. **Brown J.W., Fehrenbacher J.W., Ruzmetov M., et al.** Ross root dilation in adult patients: is preoperative aortic insufficiency associated with increased late autograft reoperation? *Ann. Thorac. Surg.* 2011; 92: 74–81.
28. **Charitos E.I., Takkenberg J.J., Hanke T., et al.** Reoperations on the pulmonary autograft and pulmonary homograft after the Ross procedure: an update on the German Dutch Ross registry. *J. Thorac. Cardiovasc. Surg.* 2012; 144(4): 813–823.
29. **Andreas M., Seebacher G., Reida E., et al.** A single-centre experience with the Ross procedure over 20 years. *Ann. Thorac. Surg.* 2014; 97: 182–188.
30. **Weimar T., Charitos E.I., Liebrich M., et al.** Quo vadis pulmonary autograft – the ross procedure in its second decade: a single-center experience in 645 patients. *Ann. Thorac. Surg.* 2014; 97(1): 167–174.
31. **Sievers H.H., Stierle U., Charitos I., et al.** Fourteen years' experience with 501 subcoronary Ross procedures: surgical details and results. *J. Thorac. Cardiovasc. Surg.* 2010; 140: 816–822.
32. **Settepani F., Kaya A., Morshuis W.J., et al.** The Ross operation: an evaluation of a single institution's experience. *Ann. Thorac. Surg.* 2005; 79: 499–504.
33. **Takkenberg J.J., Klieverik L.M., Schoof P.H., et al.** The Ross procedure: a systematic review and meta-analysis. *Circulation.* 2009; 119: 222–228.



34. **Carr-White G.S., Afoke A., Birks E.J., et al.** Aortic root characteristics of human pulmonary autografts. *Circulation*. 2000; 102: 15–21.
  35. **Juthier F., Banfi C., Vincentelli A., et al.** Modified Ross operation with reinforcement of the pulmonary autograft: six-year results. *J. Thorac. Cardiovasc. Surg.* 2010; 139: 1420–1423.
  36. **Kouchoukos N.T.** Aortic allografts and pulmonary autografts for replacement of the aortic valve and aortic root. *Ann. Thorac. Surg.* 1999; 67: 1846–1948.
  37. **Schmidtke C., Bechtel J., Noetzold A., Sievers H.** Up to seven years of experience with the Ross procedure in patients >60 years of age. *J. Am. Coll. Cardiol.* 2000; 36: 1173–1177.
  38. **Ootaki Y., Walsh M.J., Shen I., Ungerleider R.M.** Ross Procedure for patient with Marfan syndrome. *Ann. Thorac. Surg.* 2014; 97: 2186–2188.
  39. **Luciani G.B., Casali G., Favaro A., et al.** Fate of the aortic root late after Ross operation. *Circulation*. 2003; 108: 61–67.
  40. **Rabkin D.G., Reid B.B., Doty J.R.** Acute on chronic pulmonary autograft dissection. *Interact. Cardiovasc. Thorac. Surg.* 2015; 20(4): 563–564.
  41. **Kerchova L., Boodhawani M., Etienne P., et al.** Preservation of the pulmonary autograft after failure of the Ross procedure. *Eur. J. Cardiothorac. Surg.* 2010; 38: 326–332.
  42. **Luciani G.B., Lucchese G., Rita F., et al.** Reparative surgery of the pulmonary autograft: experience with Ross reoperations. *Eur. J. Cardiothorac. Surg.* 2012; 41: 1309–1315.
- 
- 

---

Адрес для корреспонденции:  
Шарифулин Р.М.  
Тел.: +7 (913) 487-08-55  
Факс: + 7 (383) 332-24-37  
E-mail: ravil-sharifulin@rambler.ru

---

Correspondence to:  
Sharifulin R.M.  
Tel.: +7 (913) 487-08-55  
Fax: + 7 (383) 332-24-37  
E-mail: ravil-sharifulin@rambler.ru