



Chapter IV: Treatment of Critical Limb Ischaemia

C. Setacci^{a,*}, G. de Donato^a, M. Teraa^{b,c}, F.L. Moll^c, J.-B. Ricco^d, F. Becker^e, H. Robert-Ebadi^e, P. Cao^f, H.H. Eckstein^g, P. De Rango^h, N. Diehmⁱ, J. Schmidli^j, F. Dick^j, A.H. Davies^k, M. Lepäntalo^{l,m}, J. Apelqvist^{n,o}

^aDepartment of Surgery, Unit of Vascular and Endovascular Surgery, University of Siena, Italy

^bDepartment of Vascular Surgery, University Medical Center Utrecht, The Netherlands

^cDepartment of Nephrology & Hypertension, University Medical Center Utrecht, The Netherlands

^dDepartment of Vascular Surgery, University Hospital of Poitiers, Poitiers, France

^eDivision of Angiology and Hemostasis, Geneva University Hospitals, Geneva, Switzerland

^fUnit of Vascular Surgery, Department of Cardiosciences, Hospital S. Camillo-Forlanini, Rome, Italy

^gClinic for Vascular Surgery, Klinikum rechts der Isar, Technische Universität München, Munich, Germany

^hUnit of Vascular and Endovascular Surgery, Hospital S. M. Misericordia, Loc. S. Andrea delle Fratte, Perugia, Italy

ⁱClinical and Interventional Angiology, Swiss Cardiovascular Centre, University Hospital Berne, Switzerland

^jDepartment of Cardiovascular Surgery, Swiss Cardiovascular Centre, University Hospital Berne, Switzerland

^kAcademic Section of Vascular Surgery, Imperial College School of Medicine, Charing Cross Hospital, London, United Kingdom

^lDepartment of Vascular Surgery, Helsinki University Central Hospital, Helsinki, Finland

^mInstitute of Clinical Medicine, Faculty of Medicine, University of Helsinki, Helsinki, Finland

ⁿThe Diabetic Foot Center at the Department of Endocrinology, Skåne University Hospital, Malmö, Sweden.

^oDivision for Clinical Sciences, University of Lund, Sweden

KEYWORDS

Guidelines;
Critical limb
ischaemia;
Limb salvage;
Open surgery;
Endovascular

Abstract Recommendations stated in the TASC II guidelines for the treatment of peripheral arterial disease (PAD) regard a heterogeneous group of patients ranging from claudicants to critical limb ischaemia (CLI) patients. However, specific considerations apply to CLI patients. An important problem regarding the majority of currently available literature that reports on revascularisation strategies for PAD is that it does not focus on CLI patients specifically and studies them as a minor part of the complete cohort. Besides the lack of data on CLI patients, studies use a variety of endpoints, and even similar endpoints are often differentially defined. These considerations result in the fact that most recommendations in this guideline are not of the highest recommendation grade.

In the present chapter the treatment of CLI is not based on the TASC II classification of atherosclerotic lesions, since definitions of atherosclerotic lesions are changing along the fast development of endovascular techniques, and inter-individual differences in interpretation of the TASC classification are problematic. Therefore we propose a classification merely based on vascular area of the atherosclerotic disease and the lesion length, which is less complex and eases the interpretation.

Lesions and their treatment are discussed from the aorta downwards to the infrapopliteal region. For a subset of lesions, surgical revascularisation is still the gold standard, such as in extensive aorto-iliac lesions, lesions of the common femoral artery and long lesions

* Corresponding author. Carlo Setacci, Viale Bracci 1, 53100 Siena, Italy.

Tel.: +39 0577 585123; mobile: +39 335 6780835; fax: +39 0577 233426. E-mail address: setacci@unisi.it (C. Setacci).

of the superficial femoral artery (>15 cm), especially when an applicable venous conduit is present, because of higher patency and limb salvage rates, even though the risk of complications is sometimes higher than for endovascular strategies.

It is however more and more accepted that an endovascular first strategy is adapted in most iliac, superficial femoral, and in some infrapopliteal lesions. The newer endovascular techniques, i.e. drug-eluting stents and balloons, show promising results especially in infrapopliteal lesions. However, most of these results should still be confirmed in large RCTs focusing on CLI patients.

At some point when there is no possibility of an endovascular nor a surgical procedure, some alternative non-reconstructive options have been proposed such as lumbar sympathectomy and spinal cord stimulation. But their effectiveness is limited especially when assessing the results on objective criteria. The additional value of cell-based therapies has still to be proven from large RCTs and should therefore still be confined to a research setting.

Altogether this chapter summarises the best available evidence for the treatment of CLI, which is, from multiple perspectives, completely different from claudication. The latter also stresses the importance of well-designed RCTs focusing on CLI patients reporting standardised endpoints, both clinical as well as procedural.

© 2011 European Society for Vascular Surgery. Published by Elsevier Ltd. All rights reserved.

1. Introduction

Recommendations stated in the TASC II guidelines for the treatment of peripheral arterial disease (PAD) regard a heterogeneous group of patients ranging from claudicants to critical limb ischaemia (CLI) patients. However, specific considerations apply to CLI patients. CLI is characterised by multi-level disease, high burden of comorbidity and limited life span. Thus decision-making in revascularisation strategies in CLI differs substantially from that in patients with claudication as wound healing, limb salvage and maintained ambulation are different treatment aims than improved walking ability and there are often considerable time constraints. Long-term patency as such is probably of less importance. The choice of endovascular treatment may be supported by presence of major comorbidities and hence high risk for open interventions.

A minority of studies specifically addresses CLI, precluding optimal decision for this specific group of patients. Moreover, different outcome measures are reported in the scarce studies that specifically focus on CLI patients. Some studies address the success of the primary intervention, exemplified by primary patency rates, while others emphasise the clinical results, such as limb salvage rates. The former is of major importance to evaluate the success of the intervention *per se* and the latter seems to be more important from a patient's perspective. So, in our opinion both should be reported in clinical studies and in a more standardised fashion as well.¹ An important problem related to the use of limb salvage as a measure of treatment success is that it is a composite endpoint affected by a variety of factors besides the revascularisation procedure *per se*. Therefore it is a valid endpoint only in randomised controlled trials. From a larger perspective, amputation-free survival has been suggested to be the most important endpoint for therapeutic studies on CLI.²

Most publications so far have been case series, cohort studies or case-control studies. The availability of well-conducted randomised controlled trials in this field is limited and therefore most recommendations in these guidelines are based on a low level of evidence. This underlines the need for future research that specifically addresses CLI

in a prospective randomised-controlled fashion with well-circumscribed standardised reported outcomes.

2. Aorto-iliac revascularisation

Aorto-iliac arterial occlusive disease (AIOD) may lead to CLI, especially if concomitant atherosclerotic disease of infra-inguinal and/or below-the-knee (BTK) arteries is present.

Surgical repair with aorto(bi)femoral bypass grafting or aorto-iliac endarterectomy has proven effective in alleviating ischaemic pain and providing good long-term patency. Aorto(bi)femoral bypass is the most efficient procedure in case of diffuse aorto-iliac disease but carries substantial risk of peri-operative mortality, morbidity and delay in return to normal activities.

An alternative approach is represented by endovascular techniques that include angioplasty, stents, stent-grafts, and plaque debulking, which offer both good clinical and procedural results and have lower procedure-related morbidity and mortality.

There are no RCTs directly comparing surgical vs. endovascular treatment of AIOD. As a result, the selection of the optimal approach for a patient with aorto-iliac occlusive disease should be based on several variables, including an assessment of the patient's general condition and extension of the disease.

2.1. Surgical treatment of AIOD

Anatomical open surgical arterial reconstructions for treatment of AIOD are: aortofemoral bypass (AFB), iliofemoral bypass (IFB), aorto-iliac endarterectomy (AIE). In rare cases a further alternative is an extra-anatomic reconstruction by descending thoracic aortofemoral bypass (DTAF).

Aorto(bi)femoral bypass is generally the preferred treatment for diffuse aorto-iliac disease in patients who are acceptable surgical candidates. Proximal anastomosis is generally performed in an end-to-end or end-to-side fashion at the level of the infrarenal aorta, without important differences between the two techniques.³ The simplest procedure that maintains adequate pelvic and colonic blood supply, according to angiographic findings, should be selected. The use of knitted gelatine-coated

polyester, knitted collagen-coated polyester or stretch polytetrafluoroethylene (PTFE) has been reported with comparable results in terms of primary and secondary patency and long-term complication rates.⁴⁻⁶ A MEDLINE (1970–2007) and Cochrane Library search for articles that report results of different open-surgical approaches for arterial reconstruction for AIOD was recently published. Studies reporting long-term primary patency data following open anatomical repair of AIOD were included, for a total of 5738 patients treated by AFB, 778 by IFB and 1490 by AIE.⁷ The operative mortality rate for AFB, IFB and AIE was 4.1%, 2.7% and 2.7%, respectively ($p < 0.0001$), while the systemic morbidity rate was 16% for AFB, 18.9% for IFB and 12.5% for AIE ($p < 0.0001$). In a sub-analysis according to clinical presentation, the 5-year primary patency in case of CLI was 79.8%, 74.1% and 81.7% for AFB, IFB and AIE, respectively ($p = 0.06$), significantly worse in comparison to 5-year patency rates for patients with intermittent claudication ($p < 0.0001$).

All three anatomical techniques for open-surgical aorto-iliac reconstructions were equally effective in terms of primary patency rates, but AIE appears to be associated with significantly lower operative mortality and systemic and local complication rates compared to the two bypass procedures. This can probably be explained by the fact that AIE is utilised predominantly for localised aorto-iliac disease and AFB and IFB may be used for more extensive disease.

DTAF is predominantly reserved for patients in whom the aforementioned reconstructions are unsuitable and is associated with higher operative mortality and graft-related complication rates and lower 5-year patency rates than the other three techniques.⁷⁻⁹

Recommendations

Aorto(bi)femoral bypass is generally the preferred treatment for diffuse aorto-iliac disease in patients who are suitable surgical candidates. **(Level 2a; Grade B)**

Aorto-iliac endarterectomy is to be recommended for patients with suitable occlusive lesions as it appears to be associated with significantly lower operative mortality and systemic and local complication rates compared with bypass procedures. **(Level 4; Grade C)**

Descending thoracic aortofemoral bypass is to be reserved for patients that cannot be otherwise revascularised as it is associated with higher operative mortality and graft-related complication rates and lower patency rates. **(Level 5; Grade D)**

2.2. Laparoscopic repair

A variety of different techniques are encompassed in the term laparoscopic AIOD repair, including totally-laparoscopic repair, hand-assisted laparoscopic repair and robotic-assisted laparoscopic repair. These are considered together for the purposes of these guidelines. Laparoscopic repair offers patients a third option for AIOD repair that provides the durability of an "open" sutured graft with a rapid recovery and reduced length of hospital stay.^{10,11}

Currently, the role of laparoscopic repair remains limited and should be confined to centres with specific expertise in laparoscopic aortic repair. This is in part due to the requirements for advanced laparoscopic practice, and also

due to the steep learning curve for this procedure. It should be noted that the cardiac risk of laparoscopic procedures should be considered to be the same as for open repair.¹² Procedures should initially only be conducted under supervision by someone experienced in laparoscopic aortic repair. Facilities to deal with emergency surgical conversion should be available at all times.

Recommendation

The role of laparoscopic repair of AIOD remains limited, but in selected patients it might represent a third option for aorto-iliac atherosclerotic disease repair. **(Level 5; Grade D)**

2.3. Extra-anatomical bypass

Extra-anatomical arterial reconstructions such as axillo-(bi)femoral bypass and crossover femoral bypass are generally reserved for patients with increased comorbidities or a hostile abdomen. For isolated unilateral iliac artery occlusive disease, for which endovascular angioplasty failed or does not seem feasible, a crossover femoro-femoral bypass can be considered as effective as an aorto-femoral or iliofemoral bypass, but with less operative morbidity. Extra-anatomical repair also allows to preserve the autonomic nerve fibres at the aortic bifurcation and has less influence on sexual function.

Recommendation

Because of the relatively low patency rates, extra-anatomical bypass should be reserved for patients who have no other alternatives for revascularisation. **(Level 4; Grade C)**

2.4. Endovascular treatment of aorto-iliac occlusive disease

There are no RCTs directly comparing surgical vs. endovascular treatment of AIOD, and therefore there is a lack of objective grounds on which the choice between the two techniques can be made.

In clinical practice, because of its minimal invasiveness, many clinicians consider endovascular therapy to be the first-line strategy, feasible and effective for the treatment of the majority of aorto-iliac atherosclerotic lesions. The technical success rate of angioplasty of iliac stenosis is nearly 100%, and the technique is also used to treat long-segment iliac occlusion. Unfortunately, CLI is seldom caused by limited aorto-iliac lesions but rather occlusive disease affecting multiple arterial segments. If focal lesions are identified, they mostly cause an inflow problem above infrainguinal occlusions in these patients.

2.4.1. Endovascular treatment of extensive aorto-iliac occlusive disease

A recent systematic review performed by Jongkind et al.¹³ identified 19 non-randomised cohort studies reporting on 1711 patients with extensive AIOD. Although the lesions treated were described adequately, unfortunately no data on the indication were included. Technical success was achieved in 86–100% of the patients with extensive AIOD, defined as less than 30% residual diameter stenosis and/or

a residual trans-lesion pressure gradient of less than 10mmHg. Clinical symptom improvement was observed in 83–100% of the patients, and mortality ranged from 1.2% to 6.7%. Although a number of procedural or peri-operative complications were reported, including distal embolisation, access-site haematomas, pseudoaneurysms, arterial ruptures, and arterial dissections, the majority could be treated using percutaneous or non-invasive techniques. Four- and 5-year primary and secondary patency after endovascular treatment of these extensive aorto-iliac lesions ranged from 60% to 86% and 80% to 98%, respectively.

In two studies retrospectively comparing endovascular therapy vs. open-surgical reconstruction for extensive AIOD, a significantly lower long-term primary patency was reported for endovascular therapy (69% vs. 93%, $p=0.013$ ¹⁴ and 74% vs. 93%, $p=0.002$ ¹⁵), while secondary patency did not differ significantly (89% vs. 100% and 96% vs. 96%). The applicability of these data on treatment decisions for CLI is affected by the low proportion of patients with CLI in these studies, 21%¹⁴ and 40%.¹⁵

Recommendations

Endovascular treatment can be considered a successful primary strategy for patients with aorto-iliac lesions, most often before or in conjunction with a distal revascularisation. Its major advantage is its less invasiveness, characterised by a lower operative morbidity-mortality. **(Level 3a; Grade C)**

Even though primary patency rates after endovascular therapy for extensive AIOD are inferior to those reported after surgery, re-interventions may be performed percutaneously. **(Level 5; Grade D)**

2.4.2. Plain balloon angioplasty vs. primary stenting

Although primary stenting has been proposed as more effective than plain balloon angioplasty for iliac atherosclerotic lesions, the evidence described in the literature does not allow clear conclusions.

The only RCT comparing the technical results and clinical outcomes of two treatment strategies (primary stenting or PTA followed by selective stenting when haemodynamic results were inadequate) concluded that patients treated with PTA and selective stent placement in the iliac artery had a better outcome for symptomatic success compared with patients treated with primary stent placement, whereas data about iliac patency, ABI, and quality of life did not support a difference between groups.¹⁶ Notably, the trial was performed in a cohort of patients with lifestyle-limiting intermittent claudication.

Nonetheless, primary stenting is now preferred in most studies for extensive aorto-iliac lesions, considering the fact that primary stenting without pre-dilatation is considered to involve less risk of causing vessel rupture and/or distal embolisation.

Recommendation

Angioplasty followed by selective stenting for PTA with inadequate result should be preferred for iliac artery occlusive disease. **(Level 2; Grade B)**

3. Infrainguinal disease

3.1. Common femoral artery (CFA)

Surgical endarterectomy of CFA lesions (CFE), isolated or within a hybrid setting, provides excellent 1- and 5-year patency rates of 93% and 91%, respectively, and secondary patency rates reaching 100%.^{17,18} Ballotta et al. confirmed the excellent long-term patency of CFE with a patch in a cohort of 117 patients (40% CLI) with 7-year primary patency rates of 96%, assisted primary patency of 100%, and 100% limb salvage.¹⁹ An advantage of surgical treatment of atherosclerotic disease of the CFA is that it provides the potential to endarterectomise adjacent diseased segments of the deep femoral artery (DFA) and the proximal superficial femoral artery (SFA) or the opportunity for hybrid iliac or SFA recanalisation. It should be noted, however, that CFE *per se* can also worsen pathology of the SFA.

There are reports on treating CFA lesions with endovascular techniques as well, although with variable results.^{20–24} In particular the early reports on angioplasty of the CFA without stenting have been associated with relatively poor results.²⁵ However, technical success rates of 100% of CFA angioplasty with primary stenting have been reported with acceptable mid-term outcome.²⁶ However, placing a stent in the CFA may increase risk of potential future surgical interventions and limit future access for endovascular revascularisation in this location. CFA stenting is likely to be an alternative for special indications and therefore RCTs comparing it with endarterectomy are hardly possible. It is further characterised by an increased risk of stent-strut fracture in this mobile segment of the arterial tree, due to repetitive hip flexion–extension and compression by the inguinal ligament.

Recommendation

Endarterectomy of atherosclerotic disease of the common femoral artery provides excellent results with limited morbidity and mortality and is the standard treatment in this location. **(Level 4; Grade C)**

3.1.1. Hybrid procedures

Concomitant disease of the external iliac artery (EIA), DFA or SFA is commonplace in CLI. In patients in whom CFE is to be performed, the direct access via the CFA can offer the opportunity to simultaneously perform endovascular treatment of the adjacent diseased EIA or SFA. These hybrid procedures have been performed with promising results and acceptable patency rates.¹⁸ Hybrid procedures of the aorto-iliac segment will be discussed here and the infrainguinal hybrid procedures will be discussed in section 3.3 on treatment of the SFA.

Aorto-iliac hybrid procedures often combine CFA surgery or infrainguinal femoropopliteal bypass surgery with aorto-iliac recanalisation, where the surgical part provides the access for the endovascular reconstruction of the diseased aorto-iliac segment. Initial technical success rates of hybrid aorto-iliac intervention generally approach 100% and peri-operative mortality rates are low.^{27–29} Reported primary patency rates after hybrid procedures for aorto-iliac occlusive disease are probably somewhat lower than for sole endovascular interventions of the aorto-iliac segment,^{29,30} with 5-year primary patency rates of 60% for hybrid

procedures²⁹ and 4-year primary patency rates of 68% (65–71%) and 77% (72–81%) for PTA and PTA with stenting, respectively.³¹ Chang et al. showed improved patency rates for stent grafts compared to bare-metal stents.²⁹ A recent report by Dostluoglu and co-workers³² reports similar results of open, endovascular and hybrid techniques for patients with similar disease complexity and even better limb salvage rates in CLI patients with complex hybrid revascularisations (TASC C or D).

Recommendations

Endovascular treatment of aorto-iliac occlusive disease in a hybrid fashion offers an acceptable alternative treatment in patients with aorto-iliac disease and concomitant common femoral artery disease that requires open surgery. **(Level 3b; Grade C)**

Stent grafts probably provide better results compared to bare-metal stents in the hybrid treatment of aorto-iliac occlusive disease. This should however be confirmed by future prospective studies. **(Level 4; Grade C)**

3.2. Deep femoral artery (DFA)

Profundoplasty is of limited value in the treatment of CLI, but can be considered in patients with stenotic lesions of the DFA and where restoration of continuous blood flow from the aorto-iliac tract to the SFA or popliteal artery is not an option. Limb salvage rates of profundoplasty have been reported to be 67% after 1 year³³ and 49% and 36% after 3 and 5 years, respectively.^{34–37} Profundoplasty is rarely performed as an isolated procedure and can be performed with or without a patch based on the intra-operative judgment by the surgeon. Besides its role for potential limb salvage profundoplasty can be of value in preserving the knee joint when amputation is deemed inevitable.³⁴

Studies on endovascular treatment of DFA obstructive disease have been mainly confined to relatively small case series, and long-term limb salvage rates are usually not reported.^{38–43} Initial technical success rates of percutaneous DFA recanalisation range from 77% to 100%,⁴⁴ but long-term results seem less favourable.^{24,43} However, more promising results of endovascular treatment of the DFA were published recently by Donas et al. in a selected group of patients (n=15) with CLI with sufficient run-off vessels, in which 3-year primary and secondary patency rates were 80% and 86.7%, respectively, and limb salvage was 93%.⁴⁵ Stenting of the DFA has also been reported,²⁶ but stenting the DFA likely hampers potential future surgical interventions in this area.

Recommendations

Revascularisation of the deep femoral artery can be considered in CLI patients without options for restoration of continuous blood flow from the aorto-iliac segment to the popliteal artery in conjunction with haemodynamically significant stenosis of the DFA. Based on currently available evidence, surgical profundoplasty is preferred over endovascular recanalisation, due to a relatively high rate of late failures of the latter. **(Level 3b; Grade C)**

Profundoplasty can be of additional value in preserving the knee joint when amputation is inevitable. **(Level 4; Grade C)**

3.3. Superficial femoral artery (SFA)

In the present guideline, lesions of the SFA are not classified according to the TASC II guidelines,⁴⁶ though these are generally regarded as the standard method of classification in treating peripheral arterial disease. The definitions of atherosclerotic lesions are changing with the rapid development of mainly endovascular techniques and devices (TASC I vs. TASC II). Furthermore, the use of the TASC classification may be problematic due to considerable inter-individual differences in interpretation.^{47–49} However, since the widespread use of the TASC classification system in the past decades most studies used this method to classify lesions under investigation. Therefore the TASC classification is still mentioned repeatedly in this guideline, but is eliminated from the treatment recommendations. For future use in research and for treatment recommendations we propose a classification system based on lesion length instead of complex loco-anatomic descriptions of lesions as provided by the TASC classification.

3.3.1. Endovascular treatment

Endovascular treatment is increasingly considered as the first-line treatment for atherosclerotic lesions of the femoropopliteal segment. Yet, the success rate of endovascular treatment of femoropopliteal lesions depends on variables such as the presence of diabetes mellitus or chronic kidney disease, stenosis vs. occlusion, lesion length and crural run-off status,⁵⁰ factors which are often unfavourable in patients with CLI.^{51,52} Despite excellent initial technical and clinical success rates of PTA of femoropopliteal artery stenoses in series studying the full range of peripheral arterial disease – most including less than 15% CLI patients – the data for CLI are far worse. This was illustrated by a meta-analysis of Muradin et al.,⁵³ which showed clearly inferior 3-year primary patency rates after recanalisation of SFA occlusions in CLI patients compared to claudicants.

Technical failure of angioplasty due to dissection or recoil has been largely reduced with the introduction of the bare metal stents,⁵⁴ but restenosis has remained a major problem precluding long-term benefit of stenting. Yet, a meta-analysis reported a 3-year patency rate of 58–68% in CLI patients.⁵³

The self-expanding nitinol stents have further improved endovascular treatment of the SFA and provide more durable results than stainless steel (balloon-expandable) stents.^{55–60} Despite the fact that these studies mainly included claudicants (proportion of CLI patients 14–89%), results of self-expanding nitinol stenting seem beneficial in CLI patients as well. Primary nitinol stenting proved beneficial compared to PTA with provisional stenting especially for longer SFA lesions (average lesion length varying from 9.8±5.4 cm to 20.35±9.46 cm).^{61–65} Limb salvage rates 36 months after stenting of the SFA in CLI patients have been reported to be 67–75%.^{66,67} For lesions <5.0 cm in length the benefit of primary stenting is clearly more debatable as has been shown in a meta-analysis by Kasapis and colleagues,⁶⁸ who showed no differences in restenosis rate and target vessel recanalisation, despite a higher immediate success rate for stenting compared to angioplasty alone.

Different studies have been published supporting endovascular treatment of long femoropopliteal (TASC C and D)

lesions with or without stenting. Han and co-workers published their results of endovascular treatment stratified by TASC lesion type and showed that in 243 CLI patients limb salvage rates 24 months after endovascular treatment were $81.0 \pm 12.9\%$, $81.1 \pm 6.8\%$, and $71.9 \pm 8.0\%$ for TASC A+B, TASC C and TASC D lesions of the SFA, respectively.⁶⁹ Similar limb salvage rates were obtained by Taneja and co-workers in CLI patients with long-segment occlusions (average 23.8 cm, range 10–39 cm) treated with bare nitinol stents, however primary patency rates were rather low with 61.5% and 27% after 6 and 12 months, respectively.⁷⁰ These studies suggest that endovascular treatment of long femoropopliteal lesions can be – at least clinically – successful.

The high restenosis rates of bare nitinol stents observed mainly in long atherosclerotic lesions of the SFA and the popliteal region provide the fertile soil for further technical innovations aiming at increasing patency rates. An important and promising innovation has been the stent graft (also referred to as covered stent, endograft, endoluminal bypass or thrupass). Most stent grafts are composed of nitinol stents covered with polytetrafluoroethylene (PTFE) and were developed to prevent restenosis due to intimal hyperplasia. Primary patency rates after 1 year for lesions <10 cm treated with PTFE stent grafts have been reported to be approximately 90% in CLI.^{71,72} However, lower and considerably varying 1-year patency rates have been recorded for longer lesions of the SFA treated with PTFE stent grafts, ranging from approximately 48% to 81%,^{73–78} and generally lower patency rates are observed in CLI patients and occlusive lesions. Despite a 69% primary patency rate at 3 years, Alimi et al. reported a 86% limb salvage rate in CLI patients treated with the PTFE stent graft for lesions with a mean length of 12.4 cm (range 2.6–30.2 cm).⁷⁶

Studies directly comparing stent grafts with plain PTA or PTA with bare stents are very limited. Saxon et al. compared stent grafts ($n=97$, 9% CLI) with PTA alone ($n=100$, 12% CLI) in a randomised fashion for treatment of SFA lesions (stenosis or occlusions) up to 13 cm. In the stent graft group a higher technical success rate and 1-year primary patency rate of 65% vs. 40% ($p=0.0003$) was observed.⁷⁹ The preliminary results of the VIBRANT trial that compares angioplasty of long SFA lesions with either the PTFE stent graft or bare nitinol stenting do not show any differences regarding primary patency at 1-year follow-up; however, secondary patency at 1 year was somewhat higher in the stent graft group. The official mid-term (3 years) follow-up results are not yet available but could prove superiority of one of both treatment modalities. An FDA-approved heparin-bonded version of the stent graft has been developed to improve patency rates. Future randomised trials still have to prove the efficacy and superiority of (heparin-bonded) stent grafts over bare nitinol stents.

There is one major concern of using covered stents, namely the potential loss of pre-existent collateral vessels with acute deterioration in case the stent graft occludes; however, this hypothesis is not yet confirmed by evidence.⁸⁰

Another proposed strategy to prevent intimal hyperplasia is represented by drug-eluting stents (DES). The first piloting trials (SIROCCO I & II) comparing sirolimus-coated stents with bare nitinol stents in the SFA failed to show important and significant differences between the two treatment

groups.^{81,82} Currently there are two trials, which have not yet published their results, that study the paclitaxel-coated Zilver pTX stent (Cook Medical, Bloomington, Indiana, USA) and the everolimus-eluting Dynalink-E (Abbott Vascular, Abbott Park, Illinois, USA), the Zilver pTX trial and the Strides study, respectively. In the Zilver pTX trial patients with moderate to severe symptomatic femoropopliteal artery disease (lesions up to 14 cm; average lesion length 6.6 cm) were randomised to undergo either traditional PTA or PTA plus Zilver pTX stent deployment ($n=479$). In the PTA group non-optimal (>30% residual stenosis or >5 mmHg pressure gradient) PTAs were again randomised to either subsequent deployment of a bare Zilver stent or the pTX version of the stent. The preliminary short-term results of the Zilver pTX trial are promising, with 12-month patency rates in the provisional stent group (after suboptimal PTA) of 89.9% and 73% for the Zilver pTX and bare Zilver stent, respectively ($p=0.01$). These results seem to be consistent and are confirmed by the 2-year follow-up data, where primary patency rates in the provisional stent group are 81.2% ($n=56$) and 62.7% ($n=56$) for the Zilver pTX and the bare-metal Zilver stent, respectively. On the other hand the Strides study ($n=106$; mean lesion length 9.0 ± 4.3 cm; 17% CLI patients) did not show any benefit of the everolimus-eluting Dynalink-E stent compared to historical controls treated with a similar non-everolimus-eluting stent, both showing a primary patency of between 60% and 70% at 12 months, despite a promising $94 \pm 2.3\%$ primary patency rate of the former.⁸³

Since long complex lesions are usually present in CLI patients, successful endovascular recanalisation of the SFA can sometimes only be performed with subintimal angioplasty (SIA). SIA has been associated with high limb salvage rates between 85% and 90% at 1 year, even despite a low 50% 1-year primary patency rate.⁸⁴ These results were recently confirmed by Bolia et al. and Setacci et al. with primary success rates of 80% and 83.5% and limb salvage rates of 85% and 88% at 1 year, respectively.^{85,86}

A major concern of the popularity of endovascular interventions, especially in complex lesions, is the potential alteration of the level for subsequent open procedures after failed endovascular intervention. Joels et al. have reported that the problem of alteration of the level of a subsequent open procedure after failed endovascular intervention is acceptable and even when the level alters it does not necessarily change clinical outcome.⁸⁷ They showed that only 23 out of the 276 patients subjected to endovascular recanalisation of the SFA presented with early failure of the procedure and that this altered the level of the subsequent open intervention in one third of the patients. Amputation due to early failure was necessary in only one patient (0.4%). However, they did not include TASC D lesions. In another study, by Gur et al.,⁸⁸ of the 192 patients who underwent PTA with primary stenting of the SFA, 69 stented arteries lost primary patency (over a 5-year period). In 10 patients open bypass was eventually required and the bypass level was changed in two of them. The risk of stent failure, loss of run-off vessels and necessity for open procedures was higher in the TASC C and D lesions. The fact that CLI patients are amenable to subsequent intervention (both open and endovascular) for limb salvage even after failed endovascular intervention is further supported by Ryer and colleagues.⁸⁹

3.3.2. Surgery

Bypass surgery has long been and still is the gold standard therapy in the treatment of long SFA lesions. The great saphenous vein is the best performing conduit for infra-inguinal bypass surgery. Above-the-knee femoropopliteal bypass has a patency rate of 77.2% at 5 years in claudicants and 69.4% in CLI patients, when saphenous vein is used as a conduit. Autologous great saphenous vein bypass below the knee has similar long-term patency rates compared to above the knee bypass.⁹⁰ Limb salvage rates of 86.9% ($\pm 7.6\%$) 2 years after non-reversed vein grafts in above-the-knee femoropopliteal bypasses have been reported for CLI.⁹¹ Venous conduits outperform prosthetic conduits irrespective of the material used (Dacron or PTFE). This also applies for arm vein conduits compared to prosthetic bypasses in CLI patients.⁹²

The BASIL trial is the only randomised trial comparing a PTA-first vs. a bypass surgery-first strategy in patients with severe limb ischaemia; it showed no differences in amputation-free survival between bypass surgery and PTA. However, for patients with a more than 2-year survival after the initial intervention, patients randomised to bypass surgery showed higher overall and amputation-free survival.^{93–95} The superiority of femoropopliteal bypass procedures compared to femoropopliteal PTA in CLI patients, especially in the long-term, is supported by a retrospective study by Korhonen et al. which used a propensity score analysis to minimise bias.⁹⁶ They showed considerable differences in favour of the bypass group (80.5% vein and 19.5% prosthetic graft) with 5-year limb salvage rates of 78.2% vs. 91.8% and survival rates of 49.2% vs. 57.1% for the PTA and bypass group, respectively. These results were still significant in the propensity score-matched pairs, with 5-year limb salvage rates of 74.3% vs. 88.2% ($p=0.031$) for the PTA vs. the bypass group, respectively.

Bypass surgery has also been randomly compared with stent graft procedures. Kedora et al.⁷⁵ reported on 100 patients with SFA occlusive disease and symptoms ranging from claudication to rest pain, with or without tissue loss, who were randomised to PTA with one or more self-expandable stent grafts ($n=50$) or prosthetic femoropopliteal above-the-knee bypass ($n=50$). The mean total length of artery stented was 25.6 ± 15 cm. Both 1-year primary and 1-year secondary patency rates – based on life-table analysis – were not significantly different between the two groups, with primary patency rates of 73.5% vs. 74.2% and secondary patency rates of 83.9% vs. 83.7% for the stent graft and bypass group, respectively. Neither did limb salvage between the two groups differ significantly. Severity of limb ischaemia (Rutherford classification) did not differ between the two groups; however, ischaemia showed a non-significant tendency to be more severe in the bypass group.⁷⁵ Later results from the same patient group showed a trend to lower patency rates for the stent graft group in the higher TASC II lesions (TASC C and D).⁷⁸ Less favourable results for stent graft procedures were reported by Lepäntalo and co-workers in a prematurely terminated (due to disadvantageous outcome in the stent graft group) randomised multicentre trial comparing stent graft procedures and prosthetic bypass surgery for occlusions (TASC II B and C occlusions) of the SFA.⁷³ In contrast to the two other studies, which

mainly included patients with intermittent claudication and did not clearly reveal data on concealment of treatment allocation, Lepäntalo et al. only included CLI patients based on rigorous inclusion criteria and properly reported concealment. They reported substantial lower primary and secondary 1-year patency rates for the stent graft group vs. the bypass group, 46% vs. 84% and 63% vs. 100%, respectively. Overall the results of these studies still favour the use of femoropopliteal bypass vs. stent graft procedures in CLI patients with long SFA lesions, especially long occlusions. Future RCTs comparing these treatment modalities (and the heparin-bonded endograft) in specific subgroups of CLI patients are necessary to allow definitive conclusions on these therapies.

3.3.3. Hybrid procedures

Hybrid procedures combining CFA surgery or distal origin bypass surgery with angioplasty of the SFA is another possibility to treat lesions of the SFA. Hybrid procedures studied are highly heterogeneous, therefore no exact numbers can be provided on patency rates and limb salvage rates. Patency rates after hybrid procedures vary considerably, with 3-year primary patency rates as high as 84% and primary patency rates as low as 58% after 41 months follow-up.^{32,97,98} However, reported limb salvage rates 3 years after the intervention are over 80%.^{32,97,99}

In a hybrid procedure it is also possible to perform remote superficial femoral artery endarterectomy (RSFAE). Patency rates of retrospective studies are promising so far, with patency rates of 61–69% at 18–33 months.¹⁰⁰ In the REVAS trial, RSFAE compared with above-knee bypass surgery has been studied for the treatment of TASC C and D lesions of the SFA. Primary patency rates after 1 year were 61% for RSFAE and 73% for bypass surgery, with similar secondary patency rates of 79%.¹⁰¹

3.3.4. Drug-eluting balloon, cryoplasty, cutting balloon, excimer laser

Drug-eluting balloons, successfully applied for angioplasty of coronary arteries, have not been widely studied in the femoropopliteal arteries. The available short-term data on the use of drug-eluting balloons for PTA of the femoropopliteal region are encouraging, however these studies have mainly focused on relatively short lesions and almost invariably address claudicants.^{102,103} Longer-term follow-up and larger randomised trials are needed to clarify whether drug-eluting balloons can be beneficial in the long term and should include sufficient numbers of CLI patients to draw reasonable conclusions in this subset of patients.

No data exist on the direct comparison of cryoplasty, cutting balloons and excimer laser with conventional endovascular treatment in patients with CLI. Cryoplasty seems not beneficial in the femoropopliteal area.^{104,105} Cutting balloons have a short design thereby limiting their use in long lesions of the SFA. Use of the excimer laser has been shown to be effective in CLI,^{106,107} however there is no evidence of superiority compared to conventional angioplasty or subintimal angioplasty in CLI.

Recommendations

A new and simplified classification system for peripheral arterial disease lesions is needed to improve inter-individual interpretation as this is problematic for the TASC classification. Therefore we would recommend a system based on lesion length to classify lesions for research applications and clinical management (EUSC classification; Fig. 1). Future research should prove the applicability and reproducibility of the classification and the additional value of a potential subdivision of stenotic vs. occlusive lesions. **(Level 5; Grade D)**

Short SFA lesions (<5 cm) are preferably treated with angioplasty. Stenting of short lesions should only be performed when suboptimal results are obtained with PTA alone. **(Level 1a; Grade B)**

The preferred treatment of intermediate SFA lesions (5–15 cm) is PTA with primary bare nitinol stenting. **(Level 1b; Grade B)**

The additional value of drug-eluting and PTFE stent grafts still has to be confirmed in CLI patients.

When autologous vein is available as a conduit, bypass surgery is the preferred treatment for long SFA lesions (>15 cm), especially in younger patients. Although the outcome after an endovascular first approach is equal in the short term to prosthetic bypass surgery for long SFA lesions in CLI patients, bypass gives better results in more fit patients and should be preferred in patients with estimated longevity >2 years. **(Level 1b; Grade B)**

In long SFA lesions (>15 cm) endovascular treatment (intraluminal or subintimal) with a stent graft seems acceptable when the patient's condition precludes an open procedure. The value of the heparin-bonded stent-graft has still to be confirmed. **(Level 3b; Grade C)**

Hybrid procedures are the preferred treatment modality irrespective of lesion length in high-risk patients not suitable for open bypass surgery or when no suitable vein is available if minimally open revascularisation is mandated, such as CFE. **(Level 2b; Grade B)**

4. Infrapopliteal disease

Despite the magnitude of the problem – currently greater than ever due to the increasing diabetic and ageing population – unexpectedly little high-quality evidence exists in the literature to support a strategy paradigm in patients with CLI and infrapopliteal disease.

Several studies have demonstrated that surgical revascularisation is the standard treatment for limb salvage in patients with CLI due to atherosclerotic disease of infrapopliteal arteries, but endovascular interventions of infrapopliteal lesions represent a far less invasive option and are now considered a valid alternative to surgical bypass in many cases.

4.1. Surgical revascularisation for infrapopliteal lesions

Unfortunately, a detailed anatomical description of the disease and relative localisation of the treatment is rarely reported in RCTs and observational studies comparing

different treatments for CLI, and no specific conclusion can be drawn for patients with isolated infrapopliteal disease.

The PREVENT III study¹⁰⁸ was a prospective, randomised, double-blinded, multi-centre phase III trial of a novel molecular therapy (edifoligide; E2F decoy) to prevent vein graft failure in patients undergoing infrainguinal revascularisation for CLI, reporting a peri-operative mortality rate of 2.7%, primary and secondary graft patency rates of 61% and 80%, and 1-year limb salvage and survival rates of 88% and 84%, respectively. In the majority of the 1404 patients who underwent surgical bypass procedures (n=914, 65%) the bypass was anastomosed at the tibial or pedal/plantar vessels distally, but no separate analysis of this subgroup was provided.

In the BASIL trial,^{93–95} only 10% of distal bypass anastomoses were located distally to the popliteal artery. Moreover, the design of the trial included only patients considered suitable for both surgical and endovascular treatment, which means that very complex cases have been treated outside the scope of the trial (probably by surgical approach).

A set of suggested objective performance goals (OPG) for evaluating the results of new catheter-based treatments in CLI has recently been elaborated, based on evidence from RCTs of patients treated by surgical vein bypass. The patient-level data from three RCTs identified 838 patients with autogenous vein bypass. The primary efficacy endpoint, defined as freedom from peri-operative (30-day) death or any major adverse limb event (amputation or major re-intervention) occurring within 1 year was 76.9%, and the primary amputation-free survival at 1 year was 76.5%. The authors suggest that these data should be considered the most suitable current framework for non-randomised comparisons, especially for evaluating outcomes after endovascular treatments for CLI. They also stress that risk stratification should be incorporated in design and reporting of studies since the CLI population is heterogeneous and the OPG thresholds differ substantially between the lower- and higher-risk procedures (based on clinical, anatomical and conduit characteristics).¹⁰⁹

Although no RCTs have selectively studied the outcomes of different graft materials for the construction of bypasses to the infrapopliteal arteries, there is a large body of evidence that vein offers better results in comparison to other graft material. Both immediate and long-term patency benefit from the use of autologous great saphenous vein, whether *in situ* or reversed. Proximal (CFA, SFA or popliteal artery) and distal anastomoses (tibial and pedal arteries) of infrainguinal bypasses may vary, depending on the extent of the atherosclerotic disease. Since the proposal of the “short bypass principle” by Veith¹¹⁰ in 1981, the use of more distal sites for the origin of the bypass have been recommended (popliteal-to-distal bypasses). The advantages include the reduction of groin dissection, the use of shorter graft material, and the decrease in operative time.

A meta-analysis¹¹¹ of popliteal-to-distal vein bypass grafts reported a 5-year primary graft patency rate of 63±4%, a secondary patency rate of 70±5%, and a foot salvage rate of 78±4%.

When the great saphenous vein is unavailable or unsuitable, alternative graft materials include autologous

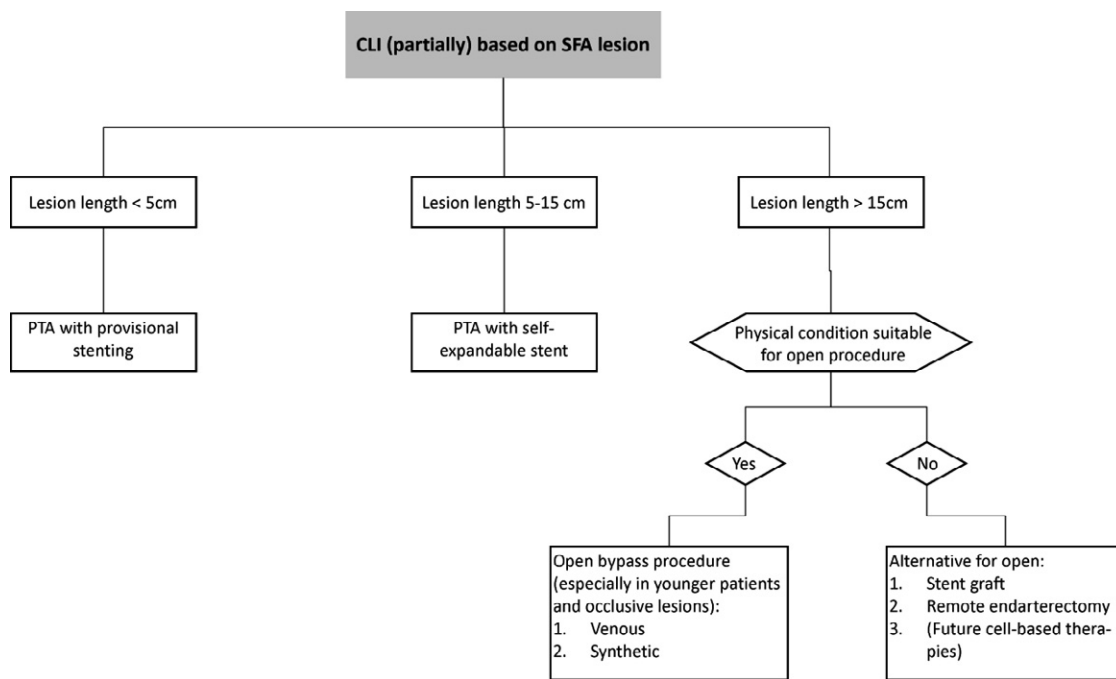


Fig. 1. EUSC classification for SFA lesions and treatment advice. In view of problems with the use of TASC guideline classification for atherosclerotic lesions – mainly poor inter-individual interpretation and hence problematic interpretation of treatment results published in the literature – we propose a simplified classification based on lesion length rather than based on complex loco-anatomic descriptions. Future research using this method has to prove its applicability and need for subclassifications, e.g., occlusive vs. stenotic lesions.

vein, allograft material (cryopreserved vein and arterial allograft) and synthetic material such as PTFE. A meta-analysis of allograft bypass grafting to infrapopliteal arteries¹¹² revealed a poor patency rate at 5 years (ranging from 19% to 30% for different grafts: cold-storage vein, cryopreserved arteries, umbilical-cord veins, and cryopreserved veins) and reduced rate of foot preservation (ranging from 55% to 60%).

Better results in cases of great saphenous vein absence come from the use of alternative autologous vein. Although this approach carries disadvantages such as the need to harvest vein from distal sites and construction of composite grafts, the meta-analysis of alternative autologous vein bypass grafts to infrapopliteal arteries¹¹³ reported results far superior to those reported for non-autologous grafts. The 5-year pooled estimates were 46.9% for primary patency, 66.5% for secondary patency, and 76.4% for foot preservation. The radial artery (or arteries) can be used for limb-salvage revascularisation when no other valuable autologous veins are available. Only short case series have been reported in the literature, almost all in diabetic patients.^{114,115}

The use of PTFE bypass to infrapopliteal arteries is associated with poor long-term outcomes. Random-effects meta-analysis¹¹⁶ yielded 5-year pooled estimates of 31% for primary graft patency, 40% for secondary graft patency, and 56% for foot preservation. Outcomes were slightly higher for a series of PTFE grafts with adjunctive procedures at distal anastomoses (composite PTFE-vein grafts, patches, cuffs and arteriovenous fistulas), compared with a series of PTFE grafts only.

Combinations of popliteal-to-distal bypass and endovascular treatment of SFA lesions have also been reported^{99,117} to improve technical success and patency rate.

Recommendations

The great saphenous vein is superior to other materials and should be preferred in bypass grafting to infrapopliteal arteries. **(Level 3b; Grade B)**

When the great saphenous vein is unavailable or unsuitable, the use of alternative autologous vein grafts (single-segment or composite) is preferable to that of allograft bypass and PTFE bypass graft. **(Level 4; Grade C)**

4.2. Endovascular revascularisation

4.2.1. Angioplasty

The primary aims of infrapopliteal angioplasty in CLI are to restore at least one straight line of blood flow to the ischaemic foot and to maintain the patency of the treated artery for as long as possible or at least as long as necessary to allow ulcer healing, pain relief and to avoid recurrence of CLI.

In the past, infrapopliteal angioplasty has been reserved for patients with short stenotic lesions or for patients who are poor candidates for bypass surgery, but in the last 5–10 years this technique has been used with increasing frequency, also for more complex lesions. Due to the evolution of techniques and the availability of dedicated materials, the endovascular first-line approach to below-the-knee (BTK) vessels should be preferred over bypass according to some authors.^{118–120}

Different endovascular approaches have been proposed, including ipsilateral, antegrade or contralateral retrograde femoral puncture, or more recently, retrograde anterior or posterior tibial puncture^{121,122} or retrograde crossing through the pedal arch (pedal-plantar loop technique).^{123,124}

Unfortunately, the level of evidence for endovascular treatment of BTK vessels is still low. Considering the absence of RCTs comparing surgical vs. endovascular techniques in patients with infrapopliteal disease, the most relevant data in the literature come from extrapolations of RCTs comparing the outcome of bypass and balloon angioplasty at different levels in patients with CLI and from the meta-analysis of retrospective case series where no biases were detected.

Another way to try to decrease bias in comparisons is to adjust differences by using propensity score analysis in large patient cohorts.^{125,126} Recently, in a study cohort comprising 1023 patients treated for CLI with 262 endovascular and 761 surgical revascularisation procedures to their crural or pedal arteries were compared. In the overall series, PTA and bypass surgery achieved similar 5-year limb salvage (75.3% vs. 76.0%), survival (47.5% vs. 43.3%), and amputation-free survival (37.7% vs. 37.3%), indicating that when feasible, infrapopliteal PTA as a first-line strategy is expected to achieve similar long-term results to bypass surgery in CLI when redo surgery is actively utilised. In a subgroup of patients who underwent isolated infrapopliteal revascularisation, PTA was associated with better limb salvage (75.5% vs. 68.0%, $p=0.042$).¹²⁷ Additionally, in 584 consecutive patients aged at least 80 years treated with either PTA ($n=277$) or bypass surgery ($n=307$) for CLI irrespective of the level of infrainguinal revascularisation, PTA achieved better results than bypass surgery after 2 years (leg salvage: 85.4% vs. 78.7%, $p=0.039$; survival: 57.7% vs. 52.3%, $p=0.014$; amputation-free survival (AFS): 53.0% vs. 44.9%, $p=0.005$). Cox regression analysis showed that increased age [relative risk (RR) 1.05, 95% confidence interval [CI] 1.02–1.08], decreased estimated glomerular filtration rate (RR 0.99, 0.99–1.00), diabetes (RR 1.30, 1.04–1.62), coronary artery disease (RR 1.36, 1.05–1.75) and bypass surgery (RR 1.55, 1.24–1.93) were associated with decreased AFS. In 95 propensity score-matched pairs, limb salvage at 2 years (88% vs. 75%; $p=0.01$) and AFS (53% vs. 45%; $p=0.033$) were significantly better after PTA. Classification and regression tree analysis suggested that PTA was associated with better 1-year AFS, especially in patients with coronary artery disease (63.8% vs. 48.9%; $p=0.008$). When feasible, a strategy of PTA first appears to achieve better results than infrainguinal bypass surgery in patients aged 80 years and older.¹²⁸

Regrettably, the only major randomised trial comparing PTA vs. surgery for peripheral arterial occlusive disease (BASIL) included patients with infrainguinal rather than isolated infrapopliteal lesions and did not report details of the anatomic segments treated and relative outcomes. Consequently, no extrapolation of data is possible, which limits analysis of the results of angioplasty vs. surgery for patients with isolated crural disease.

In a recent meta-analysis of infrapopliteal angioplasty for CLI including a large number of case series, the pooled estimate of success was $89.0\pm 2.2\%$ for immediate technical results, and the early mortality rate was 1.8%. The mid-term estimates of primary patency, secondary patency and limb salvage were assessed reliably until 36 months.¹²⁹ When compared to the results of the meta-analysis of popliteal-to-distal bypass graft, the durability of infrapopliteal angioplasty is limited, but the clinical benefit is acceptable because the limb salvage rate of 82% at

3 years is not inferior to that of surgical revascularisation, which underlines that limb salvage does not only depend on patency rates. Hence both patency rates and clinical success should be assessed when evaluating a treatment in CLI patients. Secondary interventions are much more frequent after endovascular treatment of infrapopliteal arteries. Repeated angioplasty attempts, which are not always innocuous, have some advantages over repeat bypass grafting, which is troublesome and not always feasible.

Recommendations

Endovascular treatment of infrapopliteal arteries has the potential to achieve similar limb salvage rates with less procedural morbidity and mortality than surgical bypass. Angioplasty as the first-line therapeutic modality for patients with CLI and infrapopliteal lesion is reasonable in the majority of cases, considering that the interventional procedure should not preclude future surgical intervention. **(Level 4; Grade C)**

Surgical treatment should be considered for more complex anatomical lesions of BTK vessels or in case of endovascular failure and persisting clinical symptoms of CLI. **(Level 4; Grade C)**

4.2.2. Stenting

New endovascular techniques have been proposed to improve the results of plain angioplasty, including the use of bare metal stent (balloon-expandable and self-expanding stents), drug-eluting balloon and stent, cryoplasty, laser and atherectomy. The data for these new technologies still derive predominantly from a few small RCTs and from retrospective case series, with a limited number of patients and a relatively short clinical and instrumental follow-up.

Although the first use of stents for infrapopliteal lesions was reported more than 15 years ago,¹³⁰ several concerns have been raised regarding their utilisation with respect to the risks of stent fracture, restenosis, thrombosis, and the possibly limited role of a focally acting endoprosthesis in a diffusely diseased vessel.

4.2.2.1. Balloon-expandable stent: Fering et al.¹³¹ were the first to demonstrate the safety and utility of primary stenting of infrapopliteal lesions using coronary stents, in a large retrospective series.

The first RCT on the topic was the InPeria trial published by Rand et al.¹³² The trial was a European multi-centre randomised study that investigated carbon-coated stents (a 0.014-inch coronary balloon-expandable stent with a thin coating of 0.5nm of polycrystalline carbon film to prevent thrombus formation) vs. balloon angioplasty in the infrapopliteal arteries. A total of 51 patients, with 95 lesions, were enrolled (PTA: 53 lesions in 27 patients; stent: 42 lesions in 24 patients). Inclusion criteria were isolated stenosis greater than 70% or occlusion of the tibial arteries, up to three lesions; and lesions up to 3cm with a cumulative lesion length of 9cm. Follow-up evaluation was performed with intra-arterial and/or CT angiography at 6 months by two double-blind observers. For the stent group, the cumulative primary patency at 6 months was 83.7% (70% restenosis threshold) and 79.7% (50% restenosis threshold). For PTA, the primary patency at

6 months was 61.1% (70% restenosis threshold) and 45.6% (50% restenosis threshold) ($p < 0.05$). Although the results at 6 months were superior in the stent group, 9-month clinical follow-up of an extended 88-patient group (InPeria II; 45 limbs with 69 lesions treated with PTA vs. 44 limbs with 62 lesions treated with Carbestents) showed similar levels of clinical improvement and limb salvage (96% vs. 91%, respectively) and similar 1-year patency rates of about 60%.¹³³ Until now, longer follow-up data have not been available.

Other authors reported positive results of primary stenting using coronary balloon-expandable drug-eluting stents for infrapopliteal disease in small, non-randomised, single-centre studies.^{134–138} These studies show favourable clinical results for drug-eluting stents in the early follow-up period, with significantly higher angiographic patency and less clinically driven re-interventions compared to simple angioplasty or bare-metal stent. However, these results have to be interpreted with caution because these studies were small in size and had limited follow-up. Notably most of these studies were industry-sponsored.

More recently, data from three RCTs comparing new solutions for infrapopliteal atherosclerotic disease have been presented at international meetings¹³⁹ (although manuscript publications are still awaited). These trials have found that drug-eluting stents are superior to angioplasty, or bare metal stents, in below-the-knee revascularisation. In particular, the ACHILLES trial has shown better primary patency for sirolimus-eluting balloon-expandable stents in the infrapopliteal region compared to balloon angioplasty, and the YUKON and DESTINY trials have shown a similar benefit for drug-eluting stents below the knee (respectively, a sirolimus-eluting stent and an everolimus-eluting stent) as compared to a bare metal stent. However, no significant difference in limb salvage rate was observed.

Despite the encouraging results from these RCTs for drug-eluting devices in infrapopliteal vessels, it should be noted that several inclusion criteria present in the protocols restricted study enrolment to patients with limited manifestations of tibial atherosclerotic disease, including patients with claudication (Rutherford 3) and excluding patients with severe tissue loss (Rutherford 6).

Complete longer follow-up data including clinical endpoints and wound healing assessments are expected to be published in the near future.

4.2.3. Self-expanding nitinol stents

The main restrictions of currently available bare or drug-eluting balloon-expandable stent platforms for BTK vessels are the small lengths available and the vulnerability to external compression (especially in the distal third of the anterior and posterior tibial artery). This is the reason why the majority of available studies are limited to short focal infrapopliteal lesions up to 3 cm, which are not representative of typical long BTK lesions.

Long, thin-strut, low-profile, self-expanding nitinol stents designed and engineered specifically for the infrapopliteal arteries are now commercially available, but clinical data are still limited to small non-randomised studies.^{140–142}

One RCT designed to compare PTA vs. self-expanding stent (The XXS – Balloon Angioplasty Versus Xpert Stent in CLI Patients) in patients with infrapopliteal lesions has recently completed the recruitment (180 CLI patients and

a maximum of 2 arteries with a maximum lesion length of 150 mm). Interesting data about subjects with very long BTK lesions (which might better reflect real-world cases) are expected shortly.

A collaborative systematic review and meta-analysis¹⁴³ of clinical studies focusing on BTK stenting in patients with CLI identified 18 non-randomised studies including more than 600 patients. Data showed that bailout stenting of BTK vessels, performed with either balloon-expandable or self-expanding stents for suboptimal balloon dilation, was associated with satisfactory results up to a median of 12 months after treatment: binary in-stent restenosis occurred in 25.7% (95% CI 11.6–40.0%), primary patency in 78.9% (95% CI 71.8–86.0%), improvement in Rutherford class in 91.3% (95% CI 85.5–97.1%), target vessel revascularisation in 10.1% (95% CI 6.2–13.9%), and limb salvage in 96.4% (95% CI 94.7–98.1%). Subanalyses focusing on device type showed that balloon-expandable and self-expanding stents avoiding joint segments or pedal vessels perform similarly at early and midterm follow-up. In addition, the available data suggest superiority of sirolimus-eluting stents in comparison to bare metal stents in terms of primary patency and need for re-revascularisations.

Recommendation

Short, focal infrapopliteal lesions can be treated by drug-coated or drug-eluting stents, with improved patency rate. (Level 2b; Grade B)

4.2.3.1. Bioabsorbable stent: The possibility of not having a permanent metallic implant (bioabsorbable stent scaffold technology) has emerged as an exciting technology to combine mechanical prevention of vessel recoil with the advantages of long-term perspective. The bioabsorbable stent could permit the occurrence of positive remodelling with lumen enlargement to compensate for the development of intimal hyperplasia or new lesions.

The first published data with coronary application of an absorbable polymeric everolimus-eluting stent were very promising,¹⁴⁴ revealing a nearly complete elimination of both intimal hyperplasia and the need for re-interventions at 1 year.

Unfortunately, the same promising results have not been validated for BTK vessels. The prospective multi-centre randomised trial investigating infrapopliteal absorbable magnesium stents (AMS) vs. angioplasty (AMS-INSIGHT 1 trial)¹⁴⁵ indicated that the AMS technology can be safely applied, but it did not demonstrate efficacy regarding long-term patency over standard PTA in the infrapopliteal vessels. Data from 117 patients (147 CLI limbs) showed significantly higher binary restenosis rate at 6 months (68% vs. 42%, $p = 0.01$) with a rate of lumen loss that was nearly doubled (1.4 vs. 0.7 mm, $p = 0.001$). It should be noted that the AMS stent was not drug-eluting.

Recommendation

The current-generation absorbable metal stent does not show superiority in long-term patency over standard PTA in infrapopliteal vessels. Reliable stent design modifications are required, and further clinical trials should be performed before potential widespread application of the technology. (Level 1b; Grade B)

4.2.4. Drug-eluting balloon

The concept of using a balloon catheter to directly deliver an antirestenotic drug at the site of arterial disease is of paramount interest. The plan to reduce the risk of restenosis without irreversibly modifying the structure of the vessel is a new interesting perspective, but limited clinical data are available.

Two different paclitaxel-coated balloon catheter systems are currently being compared to standard uncoated PTA balloon catheter for treatment of infrapopliteal lesion in a randomised fashion (INPACT-DEEP trial, PICCOLO trial, EURO CANAL trial).

Various angiographic and clinical efficacy measures will be evaluated to study whether paclitaxel-coated PTA balloons effectively inhibit restenosis of BTK arteries. Additionally, safety and tolerance of the drug-eluting device will be evaluated. No preliminary data are available.

It is likely that in the near future, the extent of the use of drug-coated balloons for BTK vessels in daily practice will be driven by the proof of their efficacy in reducing the restenosis rate and by the limitations of other available techniques. However, the clinical effectiveness of the drug-eluting balloons should be of crucial importance in deciding whether or not to opt for the device.

Recommendation

Drug-eluting balloon angioplasty is a promising technology for patients with CLI and infrapopliteal vessel lesions. However, prior to widespread clinical implementation, the results of pilot studies should be confirmed by RCTs with short- and long-term follow-up. **(Level 4; Grade D)**

5. Non-reconstructive option in CLI

5.1. Lumbar sympathectomy

Lumbar sympathectomy can be performed both chemically and surgically. Studies directly comparing lumbar sympathectomy to a conservative treatment in CLI patients are limited. The small number of randomised trials that have been conducted failed to show beneficial effects on hard endpoints like amputation rate, mortality or ankle-brachial pressure index.^{146,147} However, lumbar sympathectomy has a beneficial effect on subjective endpoints, such as relief of rest pain. The latter has consistently been confirmed in multiple cohort studies. These studies also suggest enhanced ulcer healing. Chemical and surgical lumbar sympathectomy seem to perform equally well¹⁴⁸ and can also be beneficial in diabetic patients.¹⁴⁹

Recommendation

Lumbar sympathectomy, either surgical or chemical, should not be considered an option to prevent amputation. However, chemical lumbar sympathectomy can be considered in CLI patients not amenable to revascularisation in order to relieve symptoms. **(Level 2a; Grade B)**

5.2. Spinal cord stimulation (SCS)

Spinal cord stimulation involves a technique where an implanted pacemaker activates the dorsal columns of the spinal cord with an epidural lead. Early studies have

reported a potential role for the device in limb salvage in patients with CLI. However, a recent meta-analysis of randomised trials that have studied the effects of SCS failed to show a beneficial effect on amputation rate or mortality.¹⁵⁰ It has been suggested that some subgroups could potentially benefit from SCS, but this could not be confirmed in the meta-analysis. Most randomised studies showed pain relief in the group treated with SCS compared to standard care.¹⁵¹ However, complication rates are considerable (12%) and treatment costs are high.^{150,152}

Recommendation

Evidence is insufficient to recommend spinal cord stimulation in the treatment of CLI. **(Level 1a; Grade A)**

5.3. Gene and cell therapy

Regenerative medicine has raised much interest as a potential therapeutic strategy in patients with peripheral arterial disease, especially critical limb ischaemia. Both angiogenic gene and cell therapy have been studied in clinical context after promising results in animal experiments. Early piloting trials have been carried out for different gene-based therapies involving vascular endothelial growth factor (VEGF), fibroblast growth factor (FGF) and hepatocyte growth factor (HGF), and showed promising results. The subsequently performed larger trials have generally failed to confirm the promising findings of the pilot trials, therefore gene therapy is still confined to research settings.¹⁵³ For example, the large TAMARIS trial randomised 525 patients with CLI unsuitable for revascularisation to treatment with non-viral FGF1 or placebo (8 intramuscular injections in the ischaemic leg, four times with 2-week intervals).¹⁵⁴ The trial could not prove that FGF is effective in reducing major amputation or death and amputation in these patients.

Studies that investigate the potential use of cell-based therapies in CLI are very heterogeneous, with varying amounts of cells administered, different administration routes, different cell sources and cell types used. Recently, Fadini et al.¹⁵⁵ performed a meta-analysis of clinical studies using cell-based therapies in patients with peripheral arterial disease. These studies almost invariably show improvement of both objective and subjective endpoints; however, conclusions based on these studies are largely limited by the small size and mainly non-randomised design of these studies. Large randomised placebo-controlled trials focusing on clinically relevant endpoints are needed to confirm the promising results and to clarify the remaining questions surrounding cell therapy, such as preferred administration route and cell source.

Recommendation

There are data to suggest promising potential of cell-based therapies in patients with CLI. However, prior to widespread clinical implementation, the results of pilot studies should be confirmed by large-scale randomised placebo-controlled trials. Until then, both cell and gene therapy should be confined to the research setting. **(Level 5; Grade D)**

Conflict of Interest/Funding

None

References

- 1 Diehm N, Baumgartner I, Jaff M, Do DD, Minar E, Schmidli J, et al. A call for uniform reporting standards in studies assessing endovascular treatment for chronic ischaemia of lower limb arteries. *Eur Heart J* 2007;**28**:798–805.
- 2 Norgren L, Hiatt WR, Dormandy JA, Hirsch AT, Jaff MR, Diehm C, et al. The next 10 years in the management of peripheral artery disease: perspectives from the 'PAD 2009' Conference. *Eur J Vasc Endovasc Surg* 2010;**40**:375–80.
- 3 Mellièrè D, Labastie J, Becquemin JP, Kassab M, Paris E. Proximal anastomosis in aortobifemoral bypass: end-to-end or end-to-side? *J Cardiovasc Surg (Torino)* 1990 Jan–Feb;**31**(1):77–80.
- 4 Prager MR, Hoblaj T, Nanobashvili J, Sporn E, Polterauer P, Wagner O, et al. Collagen- versus gelatine-coated Dacron versus stretch PTFE bifurcation grafts for aortoiliac occlusive disease: long-term results of a prospective, randomized multicenter trial. *Surgery* 2003;**134**:80–5.
- 5 Friedman SG, Lazzaro RS, Spier LN, Moccio C, Tortolani AJ. A prospective randomized comparison of Dacron and polytetrafluoroethylene aortic bifurcation grafts. *Surgery* 1995 Jan;**117**(1):7e10.
- 6 Meister RH, Schweiger H, Lang W. Knitted double-velour Dacron prostheses in aortobifemoral position: long-term performance of different coating materials. *Vasa* 1998 Nov;**27**(4):236e9.
- 7 Chiu KWH, Davies RSM, Nightingale PG, Bradbury AW, Adam DJ. Review of direct anatomical open surgical management of atherosclerotic aorto-iliac occlusive disease. *Eur J Vasc Endovasc Surg* 2010;**39**:460–71.
- 8 Criado E, Johnson Jr G, Burnham SJ, Buehrer J, Keagy BA. Descending thoracic aorta-to-iliofemoral artery bypass as an alternative to aortoiliac reconstruction. *J Vasc Surg* 1992;**15**:550–7.
- 9 Schultz RD, Sterpetti AV, Feldhaus RJ. Thoracic aorta as source of inflow in reoperation for occluded aortoiliac reconstruction. *Surgery* 1986;**100**:635–45.
- 10 Kolvenbach R, Puerschel A, Fajer S, Lin J, Wassiljew S, Schwierz E, Pinter L. Total laparoscopic aortic surgery versus minimal access techniques: review of more than 600 patients. *Vascular* 2006;**14**:186–92.
- 11 Di Centa I, Coggia M, Cerceau P, Javerliat I, Alfonsi P, Beauchet A, et al. Total laparoscopic aortobifemoral bypass: short- and middle-term results. *Ann Vasc Surg* 2008;**22**:227–32.
- 12 Moll FL, Powell JT, Fraedrich G, Verzini F, Haulon S, Waltham M, et al.; European Society for Vascular Surgery. Management of abdominal aortic aneurysms clinical practice. Guidelines of the European Society for Vascular Surgery. *Eur J Vasc Endovasc Surg* 2011 Jan;**41**(Suppl 1):S1–58.
- 13 Jongkind V, Akkersdijk GJ, Yeung KK, Wisselink W. A systematic review of endovascular treatment of extensive aortoiliac occlusive disease. *J Vasc Surg* 2010 Nov;**52**(5):1376–83.
- 14 Hans SS, DeSantis D, Siddiqui R, Khoury M. Results of endovascular therapy and aortobifemoral grafting for Transatlantic Inter-Society type C and D aortoiliac occlusive disease. *Surgery* 2008;**144**:583–9.
- 15 Kashyap VS, Pavkov ML, Bena JF, Sarac TP, O'Hara PJ, Lyden SP, et al. The management of severe aortoiliac occlusive disease: endovascular therapy rivals open reconstruction. *J Vasc Surg* 2008;**48**:1451–7.
- 16 Klein WM, van der Graaf Y, Seegers J, Spithoven JH, Buskens E, van Baal JG, et al. Dutch iliac stent trial: long-term results in patients randomized for primary or selective stent placement. *Radiology* 2006;**238**:734–44.
- 17 Kang JL, Patel VI, Conrad MF, Lamuraglia GM, Chung TK, Cambria RP. Common femoral artery occlusive disease: contemporary results following surgical endarterectomy. *J Vasc Surg* 2008;**48**:872–7.
- 18 Schrijver AM, Moll FL, De Vries JP. Hybrid procedures for peripheral obstructive disease. *J Cardiovasc Surg (Torino)* 2010;**51**:833–43.
- 19 Ballotta E, Gruppo M, Mazzalai F, Da Giau G. Common femoral artery endarterectomy for occlusive disease: an 8-year single-center prospective study. *Surgery* 2010;**147**:268–74.
- 20 Johnston KW, Rae M, Hogg-Johnston SA, Colapinto RF, Walker PM, Baird RJ, et al. 5-year results of a prospective study of percutaneous transluminal angioplasty. *Ann Surg* 1987;**206**:403–13.
- 21 Silva JA, White CJ, Quintana H, Collins TJ, Jenkins JS, Ramee SR. Percutaneous revascularization of the common femoral artery for limb ischemia. *Catheter Cardiovasc Interv* 2004;**62**:230–3.
- 22 Cotroneo AR, Iezzi R. The role of "cutting" balloon angioplasty for the treatment of short femoral bifurcation steno-obstructive disease. *Cardiovasc Intervent Radiol* 2010;**33**:921–8.
- 23 Mathisen SR, Akesson M, Lindh M, Ivancev K, Resch TA. Kissing stents in the common femoral artery bifurcation for critical limb ischemia: technical description and report of three cases. *Vascular* 2007;**15**:211–4.
- 24 Baumann F, Ruch M, Willenberg T, Dick F, Do DD, Keo HH, et al. Endovascular treatment of common femoral artery obstructions. *J Vasc Surg* 2011;**53**:1000–6.
- 25 Johnston KW, Rae M, Hogg-Johnston SA, Colapinto RF, Walker PM, Baird RJ, et al. 5-year results of a prospective study of percutaneous transluminal angioplasty. *Ann Surg* 1987;**206**:403–13.
- 26 Stricker H, Jacomella V. Stent-assisted angioplasty at the level of the common femoral artery bifurcation: midterm outcomes. *J Endovasc Ther* 2004;**11**:281–6.
- 27 Nelson PR, Powell RJ, Schermerhorn ML, Fillinger MF, Zwolak RM, Walsh DB, et al. Early results of external iliac artery stenting combined with common femoral artery endarterectomy. *J Vasc Surg* 2002;**35**:1107–13.
- 28 Schneider PA. Iliac angioplasty and stenting in association with infrainguinal bypasses: timing and techniques. *Semin Vasc Surg* 2003;**16**:291–9.
- 29 Chang RW, Goodney PP, Baek JH, Nolan BW, Rzcuidlo EM, Powell RJ. Long-term results of combined common femoral endarterectomy and iliac stenting/stent grafting for occlusive disease. *J Vasc Surg* 2008;**48**:362–7.
- 30 Klein WM, van der Graaf Y, Seegers J, Moll FL, Mali WP. Long-term cardiovascular morbidity, mortality, and reintervention after endovascular treatment in patients with iliac artery disease: The Dutch Iliac Stent Trial Study. *Radiology* 2004;**232**:491–8.
- 31 Bosch JL, Hunink MG. Meta-analysis of the results of percutaneous transluminal angioplasty and stent placement for aortoiliac occlusive disease. *Radiology* 1997;**204**:87–96.
- 32 Dosluoglu HH, Lall P, Cherr GS, Harris LM, Dryjski ML. Role of simple and complex hybrid revascularization procedures for symptomatic lower extremity occlusive disease. *J Vasc Surg* 2010;**51**:1425–35.
- 33 Towne JB, Bernhard VM, Rollins DL, Baum PL. Profundaplasty in perspective: limitations in the long-term management of limb ischemia. *Surgery* 1981;**90**:1037–46.
- 34 Rollins DL, Towne JB, Bernhard VM, Baum PL. Isolated profundaplasty for limb salvage. *J Vasc Surg* 1985;**2**:585–90.
- 35 Witz M, Shnaker A, Lehmann JM. Vascular surgical society of great Britain and Ireland: isolated femoral profundaplasty with endarterectomized superficial femoral artery for limb salvage in the elderly. *Br J Surg* 1999;**86**:706.
- 36 Miani S, Giuffrida GF, Ghilardi G, Lazaridis J, La Penna A, Giordanengo F. Indications and role of isolated profundaplasty in patients affected by limb ischemia. *Panminerva Med* 1995;**37**:204–6.
- 37 Taylor Jr LM, Baur GM, Eidemiller LR, Porter JM. Extended

- profundaplasty. Indications and techniques with results of 46 procedures. *Am J Surg* 1981;141:539–42.
- 38 Dacie JE, Daniell SJ. The value of percutaneous transluminal angioplasty of the profunda femoris artery in threatened limb loss and intermittent claudication. *Clin Radiol* 1991;44:311–6.
 - 39 Hoffmann U, Schneider E, Bollinger A. Percutaneous transluminal angioplasty (PTA) of the deep femoral artery. *Vasa* 1992;21:69–75.
 - 40 Varty K, London NJ, Ratliff DA, Bell PR, Bolia A. Percutaneous angioplasty of the profunda femoris artery: a safe and effective endovascular technique. *Eur J Vasc Surg* 1993;7:483–7.
 - 41 Bulvas M, Chochola M, Herdová J, Urbanová R. Percutaneous transluminal angioplasty of the deep femoral artery. *Cor Vasa* 1993;35:183–7.
 - 42 Silva JA, White CJ, Ramee SR, Collins TJ, Jenkins JS, Sabet S, et al. Percutaneous profundaplasty in the treatment of lower extremity ischemia: results of long-term surveillance. *J Endovasc Ther* 2001;8:75–82.
 - 43 Diehm N, Savolainen H, Mahler F, Schmidli J, Do DD, Baumgartner I. Does deep femoral artery revascularization as an isolated procedure play a role in chronic critical limb ischemia? *J Endovasc Ther* 2004;11:119–24.
 - 44 Dick P, Mlekusch W, Sabeti S, Amighi J, Schlager O, Haumer M, et al. Outcome after endovascular treatment of deep femoral artery stenosis: results in a consecutive patient series and systematic review of the literature. *J Endovasc Ther* 2006;13:221–8.
 - 45 Donas KP, Pitoulias GA, Schwindt A, Schulte S, Camci M, Schlabach R, et al. Endovascular treatment of profunda femoris artery obstructive disease: nonsense or useful tool in selected cases? *Eur J Vasc Endovasc Surg* 2010;39:308–13.
 - 46 Norgren L, Hiatt WR, Dormandy JA, Schulte S, Camci M, Schlabach R, et al. Inter-Society Consensus for the Management of Peripheral Arterial Disease (TASC II). *Eur J Vasc Endovasc Surg* 2007;33(Suppl 1):S1–75.
 - 47 Kukkonen T, Korhonen M, Halmesmäki K, Lehti L, Tiitola M, Aho P, et al. Poor inter-observer agreement on the TASC II classification of femoropopliteal lesions. *Eur J Vasc Endovasc Surg* 2010 Feb;39(2):220–4.
 - 48 Zimmermann A, Wendorff H, Schuster T, Auer F, Berger H, Eckstein HH. Interobserver agreement of the TASC II classification for supra- and infrainguinal lesions. *Eur J Vasc Endovasc Surg* 2010;39:586–90.
 - 49 Bradbury AW, Adam DJ, Bell J, Forbes JF, Fowkes FG, Gillespie I, et al.; BASIL trial Participants. Bypass versus Angioplasty in Severe Ischaemia of the Leg (BASIL) trial: A description of the severity and extent of disease using the Bollinger angiogram scoring method and the TransAtlantic Inter-Society Consensus II classification. *J Vasc Surg* 2010;51(5 Suppl):325–42S.
 - 50 Capek P, McLean GK, Berkowitz HD. Femoropopliteal angioplasty. Factors influencing long-term success. *Circulation* 1991;83:170–80.
 - 51 Rueda CA, Nehler MR, Perry DJ, McLafferty RB, Casserly IP, Hiatt WR, et al. Patterns of artery disease in 450 patients undergoing revascularization for critical limb ischemia: implications for clinical trial design. *J Vasc Surg* 2008;47:995–9.
 - 52 Faglia E, Dalla Paola L, Clerici G, Clerissi J, Graziani L, Fusaro M, et al. Peripheral angioplasty as the first-choice revascularization procedure in diabetic patients with critical limb ischemia: prospective study of 993 consecutive patients hospitalized and followed between 1999 and 2003. *Eur J Vasc Endovasc Surg* 2005;29:620–7.
 - 53 Muradin GS, Bosch JL, Stijnen T, Hunink MG. Balloon dilation and stent implantation for treatment of femoropopliteal arterial disease: meta-analysis. *Radiology* 2001 Oct;221(1):137–45.
 - 54 Dormandy JA, Rutherford RB. Management of peripheral arterial disease (PAD). TASC Working Group. TransAtlantic Inter-Society Consensus (TASC). *J Vasc Surg* 2000;31:S1–296.
 - 55 Sabeti S, Schillinger M, Amighi J, Sherif C, Mlekusch W, Ahmadi R, et al. Primary patency of femoropopliteal arteries treated with nitinol versus stainless steel self-expanding stents: propensity score-adjusted analysis. *Radiology* 2004;232:516–21.
 - 56 Kawamura Y, Ishii H, Aoyama T, Tanaka M, Takahashi H, Kumada Y, et al. Nitinol stenting improves primary patency of the superficial femoral artery after percutaneous transluminal angioplasty in hemodialysis patients: a propensity-matched analysis. *J Vasc Surg* 2009;50:1057–62.
 - 57 Henry M, Henry I, Klonaris C, Hugel M. Clinical experience with the OptiMed sinus stent in the peripheral arteries. *J Endovasc Ther* 2003;10:772–9.
 - 58 Vogel TR, Shindelman LE, Nackman GB, Graham AM. Efficacious use of nitinol stents in the femoral and popliteal arteries. *J Vasc Surg* 2003;38:1178–84.
 - 59 Mewissen MW. Self-expanding nitinol stents in the femoropopliteal segment: technique and mid-term results. *Tech Vasc Interv Radiol* 2004;7:2–5.
 - 60 Laird JR, Katzen BT, Scheinert D, Lammer J, Carpenter J, Buchbinder M, et al. Nitinol stent implantation versus balloon angioplasty for lesions in the superficial femoral artery and proximal popliteal artery: twelve-month results from the RESILIENT randomized trial. *Circ Cardiovasc Interv* 2010;3:267–76.
 - 61 Dick P, Wallner H, Sabeti S, Loewe C, Mlekusch W, Lammer J, et al. Balloon angioplasty versus stenting with nitinol stents in intermediate length superficial femoral artery lesions. *Catheter Cardiovasc Interv* 2009;74:1090–5.
 - 62 Schillinger M, Sabeti S, Loewe C, Dick P, Amighi J, Mlekusch W, et al. Balloon angioplasty versus implantation of nitinol stents in the superficial femoral artery. *N Engl J Med* 2006;354:1879–88.
 - 63 Schillinger M, Sabeti S, Dick P, Amighi J, Mlekusch W, Schlager O, et al. Sustained benefit at 2 years of primary femoropopliteal stenting compared with balloon angioplasty with optional stenting. *Circulation* 2007;115:2745–9.
 - 64 Krankenberg H, Schlüter M, Steinkamp HJ, Bürgelin K, Scheinert D, Schulte KL, et al. Nitinol stent implantation versus percutaneous transluminal angioplasty in superficial femoral artery lesions up to 10 cm in length: the femoral artery stenting trial (FAST). *Circulation* 2007;116:285–92.
 - 65 Hu H, Zhang H, He Y, Jin W, Tian L, Chen X, et al. Endovascular nitinol stenting for long occlusive disease of the superficial femoral artery in critical limb ischemia: a single-center, mid-term result. *Ann Vasc Surg* 2011;25:210–6.
 - 66 Surowiec SM, Davies MG, Eberly SW, Rhodes JM, Illig KA, Shortell CK, et al. Percutaneous angioplasty and stenting of the superficial femoral artery. *J Vasc Surg* 2005;41:269–78.
 - 67 Ichnat DM, Duong ST, Taylor ZC, Leon LR, Mills JL Sr, Goshima KR, et al. Contemporary outcomes after superficial femoral artery angioplasty and stenting: the influence of TASC classification and runoff score. *J Vasc Surg* 2008;47:967–74.
 - 68 Kasapis C, Henke PK, Chetcuti SJ, Koenig GC, Rectenwald JE, Krishnamurthy VN, et al. Routine stent implantation vs. percutaneous transluminal angioplasty in femoropopliteal artery disease: a meta-analysis of randomized controlled trials. *Eur Heart J* 2009 Jan;30(1):44–55.
 - 69 Han DK, Shah TR, Ellozy SH, Vouyouka AG, Marin ML, Faries PL. The success of endovascular therapy for all TransAtlantic Society Consensus graded femoropopliteal lesions. *Ann Vasc Surg* 2011;25:15–24.
 - 70 Taneja M, Tay KH, Dewan A, Sebastian MG, Pasupathy S, Lin SE, et al. Bare nitinol stent enabled recanalization of long-segment, chronic total occlusion of superficial femoral and adjacent

- proximal popliteal artery in diabetic patients presenting with critical limb ischemia. *Cardiovasc Revasc Med* 2010;11:232–5.
- 71 Hartung O, Otero A, Dubuc M, Boufi M, Barthelemy P, Aissi K, et al. Efficacy of Hemobahn in the treatment of superficial femoral artery lesions in patients with acute or critical ischemia: a comparative study with claudicants. *Eur J Vasc Endovasc Surg* 2005;30:300–6.
 - 72 Railo M, Roth WD, Edgren J, Biancari F, Ikonen T, Albäck A, et al. Preliminary results with endoluminal femoropopliteal thrombectomy. *Ann Chir Gynaecol* 2001;90:15–8.
 - 73 Lepäntalo M, Laurila K, Roth WD, Rossi P, Lavonen J, Mäkinen K, et al.; Scandinavian Thrupass Study Group. PTFE bypass or thrupass for superficial femoral artery occlusion? A randomised controlled trial. *Eur J Vasc Endovasc Surg* 2009;37:578–84.
 - 74 Bauermeister G. Endovascular stent-grafting in the treatment of superficial femoral artery occlusive disease. *J Endovasc Ther* 2001;8:315–20.
 - 75 Kedora J, Hohmann S, Garrett W, Munschaur C, Theune B, Gable D. Randomized comparison of percutaneous Viabahn stent grafts vs prosthetic femoral-popliteal bypass in the treatment of superficial femoral arterial occlusive disease. *J Vasc Surg* 2007;45:10–6.
 - 76 Alimi YS, Hakam Z, Hartung O, Boufi M, Barthélemy P, Aissi K, et al. Efficacy of Viabahn in the treatment of severe superficial femoral artery lesions: which factors influence long-term patency? *Eur J Vasc Endovasc Surg* 2008;35:346–52.
 - 77 Farraj N, Srivastava A, Pershad A. One-year outcomes for recanalization of long superficial femoral artery chronic total occlusions with the Viabahn stent graft. *J Invasive Cardiol* 2009;21:278–81.
 - 78 McQuade K, Gable D, Hohman S, Pearl G, Theune B. Randomized comparison of ePTFE/nitinol self-expanding stent graft vs prosthetic femoral-popliteal bypass in the treatment of superficial femoral artery occlusive disease. *J Vasc Surg* 2009;49:109–15, 116.
 - 79 Saxon RR, Dake MD, Volgelzang RL, Katzen BT, Becker GJ. Randomized, multicenter study comparing expanded polytetrafluoroethylene-covered endoprostheses placement with percutaneous transluminal angioplasty in the treatment of superficial femoral artery occlusive disease. *J Vasc Interv Radiol* 2008;19:823–32.
 - 80 Saxon RR, Coffman JM, Gooding JM, Ponc DJ. Long-term patency and clinical outcome of the Viabahn stent-graft for femoropopliteal artery obstructions. *J Vasc Interv Radiol* 2007;18:1341–9.
 - 81 Duda SH, Bosiers M, Lammer J, Scheinert D, Zeller T, Oliva V, et al. Drug-eluting and bare nitinol stents for the treatment of atherosclerotic lesions in the superficial femoral artery: long-term results from the SIROCCO trial. *J Endovasc Ther* 2006;13:701–10.
 - 82 Duda SH, Bosiers M, Lammer J, Scheinert D, Zeller T, Tielbeek A, et al. Sirolimus-eluting versus bare nitinol stent for obstructive superficial femoral artery disease: the SIROCCO II trial. *J Vasc Interv Radiol* 2005 Mar;16(3):331–8.
 - 83 Lammer J, Bosiers M, Zeller T, Schillinger M, Boone E, Zaugg MJ, et al. First clinical trial of nitinol self-expanding everolimus-eluting stent implantation for peripheral arterial occlusive disease. *J Vasc Surg* 2011 Aug;54(2):394–401.
 - 84 Met R, Van Lienden KP, Koelemay MJ, Bipat S, Legemate DA, Reekers JA. Subintimal angioplasty for peripheral arterial occlusive disease: a systematic review. *Cardiovasc Intervent Radiol* 2008;31:687–97.
 - 85 Bolia A. Subintimal angioplasty in lower limb ischaemia. *J Cardiovasc Surg (Torino)* 2005;46:385–94.
 - 86 Setacci C, Chisci E, de Donato G, Setacci F, Iacoponi F, Galzerano G. Subintimal angioplasty with the aid of a re-entry device for TASC C and D lesions of the SFA. *Eur J Vasc Endovasc Surg* 2009;38:76–87.
 - 87 Joels CS, York JW, Kalbaugh CA, Cull DL, Langan 3rd EM, Taylor SM. Surgical implications of early failed endovascular intervention of the superficial femoral artery. *J Vasc Surg* 2008;47:562–5.
 - 88 Gur I, Lee W, Akopian G, Rowe VL, Weaver FA, Katz SG. Clinical outcomes and implications of failed infrainguinal endovascular stents. *J Vasc Surg* 2011;53:658–67.
 - 89 Ryer EJ, Trocciola SM, DeRubertis B, Lam R, Hyncek RL, Karwowski J, et al. Analysis of outcomes following failed endovascular treatment of chronic limb ischemia. *Ann Vasc Surg* 2006;20:440–6.
 - 90 Pereira CE, Albers M, Romiti M, Brochado-Neto FC, Pereira CA. Meta-analysis of femoropopliteal bypass grafts for lower extremity arterial insufficiency. *J Vasc Surg* 2006;44:510–7.
 - 91 De LN, Brochado-Neto FC, Romiti M, Kikuchi M, dos Reis JM, Durazzo AE, et al. Preferential use of nonreversed vein grafts in above-knee femoropopliteal bypasses for critical ischemia: midterm outcome. *Ann Vasc Surg* 2008;22:668–75.
 - 92 Arvela E, Söderström M, Albäck A, Aho PS, Venermo M, Lepäntalo M. Arm vein conduit vs prosthetic graft in infrainguinal revascularization for critical leg ischemia. *J Vasc Surg* 2010;52:616–23.
 - 93 Adam DJ, Beard JD, Cleveland T, Bell J, Bradbury AW, Forbes JF, et al. Bypass versus angioplasty in severe ischaemia of the leg (BASIL): multicentre, randomised controlled trial. *Lancet* 2005;366:1925–34.
 - 94 Bradbury AW, Adam DJ, Bell J, Forbes JF, Fowkes FG, Gillespie I, et al. Bypass versus Angioplasty in Severe Ischaemia of the Leg (BASIL) trial: Analysis of amputation free and overall survival by treatment received. *J Vasc Surg* 2010;51:185–315.
 - 95 Bradbury AW, Adam DJ, Bell J, Forbes JF, Fowkes FG, Gillespie I, et al. Bypass versus Angioplasty in Severe Ischaemia of the Leg (BASIL) trial: An intention-to-treat analysis of amputation-free and overall survival in patients randomized to a bypass surgery-first or a balloon angioplasty-first revascularization strategy. *J Vasc Surg* 2010;51:55–175.
 - 96 Korhonen M, Biancari F, Söderström M, Arvela E, Halmesmäki K, Albäck A, et al. Femoropopliteal balloon angioplasty vs. bypass surgery for CLI: a propensity score analysis. *Eur J Vasc Endovasc Surg* 2011;41:378–84.
 - 97 Schanzer A, Owens CD, Conte MS, Belkin M. Superficial femoral artery percutaneous intervention is an effective strategy to optimize inflow for distal origin bypass grafts. *J Vasc Surg* 2007;45:740–3.
 - 98 Lantis J, Jensen M, Benvenisty A, Mendes D, Gendics C, Todd G. Outcomes of combined superficial femoral endovascular revascularization and popliteal to distal bypass for patients with tissue loss. *Ann Vasc Surg* 2008;22:366–71.
 - 99 Schneider PA, Caps MT, Ogawa DY, Hayman ES. Intraoperative superficial femoral artery balloon angioplasty and popliteal to distal bypass graft: an option for combined open and endovascular treatment of diabetic gangrene. *J Vasc Surg* 2001;33:955–62.
 - 100 Rosenthal D, Martin JD, Smeets L, Devries JP, Gisbertz S, Wellons ED, et al. Remote superficial femoral artery endarterectomy and distal aSpire stenting: results of a multinational study at three-year follow-up. *J Cardiovasc Surg (Torino)* 2006;47:385–91.
 - 101 Gisbertz SS, Ramzan M, Tutein Nolthenius RP, van der Laan L, Overtom TT, Moll FL, et al. Short-term results of a randomized trial comparing remote endarterectomy and supragenicular bypass surgery for long occlusions of the superficial femoral artery [the REVAS trial]. *Eur J Vasc Endovasc Surg* 2009;37:68–76.
 - 102 Werk M, Langner S, Reinkensmeier B, Boettcher HF, Tepe G,

- Dietz U, et al. Inhibition of restenosis in femoropopliteal arteries: paclitaxel-coated versus uncoated balloon: femoral paclitaxel randomized pilot trial. *Circulation* 2008 Sep 23; **118**(13):1358–65.
- 103 Tepe G, Zeller T, Albrecht T, Heller S, Schwarzwälder U, Beregi JP, Claussen CD, et al. Local delivery of paclitaxel to inhibit restenosis during angioplasty of the leg. *N Engl J Med* 2008 Feb 14; **358**(7):689–99.
- 104 Gonzalo B, Solanich T, Bellmunt S, Herranz C, González E, Arnedo G, et al. Cryoplasty as endovascular treatment in the femoropopliteal region: hemodynamic results and follow-up at one year. *Ann Vasc Surg* 2010; **24**:680–5.
- 105 Spiliopoulos S, Katsanos K, Karnabatidis D, Diamantopoulos A, Kagadis GC, Christeas N, et al. Cryoplasty versus conventional balloon angioplasty of the femoropopliteal artery in diabetic patients: long-term results from a prospective randomized single-center controlled trial. *Cardiovasc Intervent Radiol* 2010; **33**:929–38.
- 106 Laird JR, Zeller T, Gray BH, Scheinert D, Vranic M, Reiser C, et al. Limb salvage following laser-assisted angioplasty for critical limb ischemia: results of the LACI multicenter trial. *J Endovasc Ther* 2006; **13**:1–11.
- 107 Laird Jr J, Reiser C, Biamino G, Zeller T. Excimer laser assisted angioplasty for the treatment of critical limb ischemia. *J Cardiovasc Surg (Torino)* 2004; **45**:239–48.
- 108 Conte MS, Bandyk DF, Clowes AW, Moneta GL, Seely L, Lorenz TJ, et al.; PREVENT III Investigators. Results of PREVENT III: a multicenter, randomized trial of edifoligide for the prevention of vein graft failure in lower extremity bypass surgery. *J Vasc Surg* 2006 Apr; **43**(4):742–51; discussion 751.
- 109 Conte MS, Geraghty PJ, Bradbury AW, Hevelone ND, Lipsitz SR, Moneta GL, et al. Suggested objective performance goals and clinical trial design for evaluating catheter-based treatment of critical limb ischemia. *J Vasc Surg* 2009; **50**:1462–73.e1–3.
- 110 Veith FJ, Gupta SK, Samson RH, Flores SW, Janko G, Scher LA. Superficial femoral and popliteal arteries as inflow sites for distal bypasses. *Surgery* 1981; **90**:980–90.
- 111 Albers M, Romiti M, Brochado-Neto FC, De Luccia N, Pereira CA. Meta-analysis of popliteal-to-distal vein bypass grafts for critical ischemia. *J Vasc Surg* 2006 Mar; **43**(3):498–503.
- 112 Albers M, Romiti M, Pereira CA, Antonini M, Wulkan M. Meta-analysis of allograft bypass grafting to infrapopliteal arteries. *Eur J Vasc Endovasc Surg* 2004 Nov; **28**(5):462–72.
- 113 Albers M, Romiti M, Brochado-Neto FC, Pereira CA. Meta-analysis of alternate autologous vein bypass grafts to infrapopliteal arteries. *J Vasc Surg* 2005 Sep; **42**(3):449–55.
- 114 Leshnower BG, Leshnower LE, Leshnower AC. Adjunctive uses of the radial artery for emergency infrapopliteal bypass in patients presenting with acute limb-threatening ischemia. *Vasc Endovasc Surg* 2007; **41**:348–51.
- 115 Teodorescu VJ, Chun JK, Morrissey NJ, Faries PL, Hollier LH, Marin ML. Radial artery flow-through graft: a new conduit for limb salvage. *J Vasc Surg* 2003; **37**:816–20.
- 116 Albers M, Battistella VM, Romiti M, Rodrigues AA, Pereira CA. Meta-analysis of polytetrafluoroethylene bypass grafts to infrapopliteal arteries. *J Vasc Surg* 2003 Jun; **37**(6):1263–9.
- 117 Woelfle KD, Bruijnen H, Reeps C, Reutemann S, Wack C, Campbell P, et al. Tibioperoneal arterial lesions and critical foot ischaemia: successful management by the use of short vein grafts and percutaneous transluminal angioplasty. *Vasa* 2000; **29**:207–14.
- 118 Haider SN, Kavanagh EG, Forlee M, Colgan MP, Madhavan P, Moore DJ, et al. Two-year outcome with preferential use of infrainguinal angioplasty for critical ischemia. *J Vasc Surg* 2006; **43**:504–12.
- 119 Kudo T, Chandra FA, Ahn SS. The effectiveness of percutaneous transluminal angioplasty for the treatment of critical limb ischemia: a 10-year experience. *J Vasc Surg* 2005; **41**:423–35.
- 120 Bosiers M, Hart JP, Deloose K, Verbist J, Peeters P. Endovascular therapy as the primary approach for limb salvage in patients with critical limb ischemia: experience with 443 infrapopliteal procedures. *Vascular* 2006; **14**:63–9.
- 121 Gandini R, Pipitone V, Stefanini M, Maresca L, Spinelli A, Colangelo V, et al. The “Safari” technique to perform difficult subintimal infragenicular vessels. *Cardiovasc Intervent Radiol* 2007 May–Jun; **30**(3):469–73.
- 122 Montero-Baker M, Schmidt A, Bräunlich S, Ulrich M, Thieme M, Biamino G, et al. Retrograde approach for complex popliteal and tibioperoneal occlusions. *J Endovasc Ther* 2008 Oct; **15**(5):594–604.
- 123 Fusaro M, Dalla Paola L, Biondi-Zoccai G. Pedal-plantar loop technique for a challenging below-the-knee chronic total occlusion: a novel approach to percutaneous revascularization in critical lower limb ischemia. *J Invasive Cardiol* 2007 Feb; **19**(2):E34–7.
- 124 Manzi M, Fusaro M, Ceccacci T, Erente G, Dalla Paola L, Brocco E. Clinical results of below-the knee intervention using pedal-plantar loop technique for the revascularization of foot arteries. *J Cardiovasc Surg (Torino)* 2009 Jun; **50**(3):331–7.
- 125 Kechagias A, Perälä J, Ylönen K, Mahar MA, Biancari F. Validation of the Finnvasc score in infrainguinal percutaneous transluminal angioplasty for critical lower limb ischemia. *Ann Vasc Surg* 2008; **22**:547–51.
- 126 Arvela E, Söderström M, Korhonen M, Halmesmäki K, Albäck A, Lepäntalo M, et al. Finnvasc score and modified Prevent III score predict long-term outcome after infrainguinal surgical and endovascular revascularization for critical limb ischemia. *Vasc Surg* 2010; **52**:1218–25.
- 127 Söderström MI, Arvela EM, Korhonen M, Halmesmäki KH, Albäck AN, Biancari F, et al. Infrapopliteal percutaneous transluminal angioplasty versus bypass surgery as first-line strategies in critical leg ischemia: a propensity score analysis. *Ann Surg* 2010; **252**:765–73.
- 128 Arvela E, Venermo M, Söderström M, Korhonen M, Halmesmäki K, Albäck A, et al. Infrainguinal percutaneous transluminal angioplasty or bypass surgery in patients aged 80 years and older with critical leg ischaemia. *Br J Surg* 2011; **98**:518–26.
- 129 Romiti M, Albers M, Brochado-Neto FC, Durazzo AE, Pereira CA, De Luccia N. Meta-analysis of infrapopliteal angioplasty for chronic critical limb ischemia. *J Vasc Surg* 2008; **47**:975–81.
- 130 Dorros G, Hall P, Prince C. Successful limb salvage after recanalization of an occluded infrapopliteal artery utilizing a balloon expandable (Palmaz-Schatz) stent. *Catheter Cardiovasc Diagn* 1993; **28**:83–8.
- 131 Feiring AJ, Wesolowski AA, Lade S. Primary stent-supported angioplasty for treatment of below-knee critical limb ischemia and severe claudication: early and one-year outcomes. *J Am Coll Cardiol* 2004; **44**:2307–14.
- 132 Rand T, Basile A, Cejna M, Fleischmann D, Funovics M, Gschwendtner M, et al. PTA versus carbofilm-coated stents in infrapopliteal arteries: pilot study. *Cardiovasc Intervent Radiol* 2006; **29**:29–38.
- 133 Rand T, Jahnke T, Lammer J, Rabbia C, Maynar M, Scheinert D, et al. Stents vs. PTA: infra-popliteal randomized trial [abstract]. In: Proceedings of the CIRSE Annual Meeting, September 13–17, 2008, Copenhagen, Denmark; p. 296.
- 134 Siablis D, Karnabatidis D, Katsanos K, Kagadis GC, Kraniotis P, Diamantopoulos A, et al. Sirolimus-eluting versus bare stents after suboptimal infrapopliteal angioplasty for critical limb ischemia: enduring 1-year angiographic and clinical benefit. *J Endovasc Ther* 2007; **14**:241–50.
- 135 Bosiers M, Deloose K, Verbist J, Peeters P. Percutaneous transluminal angioplasty for treatment of “below-the-knee”

- critical limb ischemia: early outcomes following the use of sirolimus-eluting stents. *J Cardiovasc Surg (Torino)* 2006;**47**:171–6.
- 136 Scheinert D, Ulrich M, Scheinert S, Sax J, Bräunlich S, Biamino G. Comparison of sirolimus-eluting vs bare-metal stents for the treatment of infrapopliteal obstructions. *Eurointervention* 2006;**2**:169–74.
 - 137 Commeau P, Barragan P, Roquebert PO. Sirolimus for below the knee lesions: mid-term results of SiroBTK study. *Catheter Cardiovasc Interv* 2006;**68**:793–8.
 - 138 Siablis D, Karnabatidis D, Katsanos K, Diamantopoulos A, Christeas N, Kagadis GC. Infrapopliteal application of paclitaxel-eluting stents for critical limb ischemia: midterm angiographic and clinical results. *J Vasc Interv Radiol* 2007;**18**:1351–61.
 - 139 Latest Update on Clinical Trials: DESTINY, YUKON & ACHILLES. www.leipzig-interventional-course.com, accessed 17 April 2011.
 - 140 Kickuth R, Keo HH, Triller J, Ludwig K, Do DD. Initial clinical experience with the 4-F self-expanding XPERT stent system for infrapopliteal treatment of patients with severe claudication and critical limb ischemia. *J Vasc Interv Radiol* 2007;**18**:703–8.
 - 141 Peregrin JH, Smířová S, Koznar B, Novotný J, Kovác J, Lastovicková J, et al. Selfexpandable stent placement in infrapopliteal arteries after unsuccessful angioplasty failure: one-year follow-up. *Cardiovasc Intervent Radiol* 2008;**31**:860–4.
 - 142 Tepe G, Zeller T, Heller S, Wiskirchen J, Fischmann A, Coerper S, et al. Self-expanding nitinol stents for treatment of infragenicular arteries following unsuccessful balloon angioplasty. *Eur Radiol* 2007;**17**:2088–95.
 - 143 Biondi-Zoccai GG, Sangiorgi G, Lotrionte M, Feiring A, Commeau P, Fusaro M, et al. Infragenicular stent implantation for below-the-knee atherosclerotic disease: clinical evidence from an international collaborative meta-analysis on 640 patients. *J Endovasc Ther* 2009 Jun;**16**(3):251–60.
 - 144 Ormiston JA, Serruys PW, Regar E, Dudek D, Thuesen L, Webster MW, et al. A bioabsorbable everolimus-eluting coronary stent system for patients with single de-novo coronary artery lesions (ABSORB): a prospective open-label trial. *Lancet* 2008;**371**:899–907.
 - 145 Bosiers M, Peeters P, D'Archambeau O, Hendriks J, Pilger E, Düber C, et al.; AMS INSIGHT Investigators. AMS INSIGHT –absorbable metal stent implantation for treatment of below-the-knee critical limb ischemia: 6-month analysis. *Cardiovasc Intervent Radiol* 2009;**32**:424–35.
 - 146 Ruiz-Aragon J, Marquez CS. [Effectiveness of lumbar sympathectomy in the treatment of occlusive peripheral vascular disease in lower limbs: systematic review]. *Med Clin (Barc)* 2010;**134**:477–82.
 - 147 Sanni A, Hamid A, Dunning J. Is sympathectomy of benefit in critical leg ischaemia not amenable to revascularisation? *Interact Cardiovasc Thorac Surg* 2005;**4**:478–83.
 - 148 Holiday FA, Barendregt WB, Slappendel R, Crul BJ, Buskens FG, van der Vliet JA. Lumbar sympathectomy in critical limb ischaemia: surgical, chemical or not at all? *Cardiovasc Surg* 1999;**7**:200–2.
 - 149 Perez-Burkhardt JL, Gonzalez-Fajardo JA, Martin JF, Carpintero Mediavilla LA, Mateo Gutierrez AM. Lumbar sympathectomy as isolated technique for the treatment of lower limbs chronic ischemia. *J Cardiovasc Surg (Torino)* 1999;**40**:7–13.
 - 150 Klomp HM, Steyerberg EW, Habbema JD, van Urk H; ESES study group. What is the evidence on efficacy of spinal cord stimulation in (subgroups of) patients with critical limb ischemia? *Ann Vasc Surg* 2009;**23**:355–63.
 - 151 Pedrini L, Magnoni F. Spinal cord stimulation for lower limb ischemic pain treatment. *Interact Cardiovasc Thorac Surg* 2007;**6**:495–500.
 - 152 Simpson EL, Duenas A, Holmes MW, Papaioannou D, Chilcott J. Spinal cord stimulation for chronic pain of neuropathic or ischaemic origin: systematic review and economic evaluation. *Health Technol Assess* 2009;**13**:iii, ix–xiii, 154.
 - 153 Germani A, Di CC, Pompilio G, Biglioli P, Capogrossi MC. Regenerative therapy in peripheral artery disease. *Cardiovasc Ther* 2009;**27**:289–304.
 - 154 Belch J, Hiatt WR, Baumgartner I, Driver IV, Nikol S, Norgren L, et al.; TAMARIS Committees and Investigators. Effect of fibroblast growth factor NV1FGF on amputation and death: a randomised placebo-controlled trial of gene therapy in critical limb ischaemia. *Lancet* 2011;**377**:1929–37.
 - 155 Fadini GP, Agostini C, Avogaro A. Autologous stem cell therapy for peripheral arterial disease meta-analysis and systematic review of the literature. *Atherosclerosis* 2010;**209**:10–7.