

STENTING OF THE CAROTID ARTERY WITH CGUARD AND ACCULINK STENTS: INTERIM RESULTS OF A RANDOMIZED TRIAL

BUGUROV S.V., KARPENKO A.A., IGNATENKO P.V.,
POPOVA I.V., STARODUBTSEV V.B., SAAYA SH.B., ZEIDLITS G.A.,
BRUSYANSKAYA A.S., FATULLOEVA SH.SH., BOCHKOV I.V., OSIPOVA O.S.

Centre of Vascular and Hybrid Surgery, National Medical Research Centre named after Academician E.N. Meshalkin under the RF Ministry of Public Health, Novosibirsk

Objective. The study was undertaken to evaluate safety and efficacy of carotid stents Acculink (open-cell carotid stent) and CGuard (closed-cell type stent) in treatment of patients presenting with atherosclerotic lesions of carotid arteries.

Patients and methods. The study enrolled a total of 50 patients diagnosed with haemodynamically significant stenosis of the carotid artery and divided into two groups of 25 patients each. Group One patients received Acculink stents and Group Two patients underwent implantation of CGuard stents. Ultrasonographic examination was performed in all patients before and after surgery, as well as at 6 and 12 months thereafter; magnetic resonance imaging of the brain was carried out before and after surgery (at 24–48 postoperative hours and on POD 30). The entire period of follow up included 5 examinations of each patient by a neurologist. The obtained findings were statistically analysed using the Statistica 12 software (StatSoft, USA). The level of deviation of the null hypothesis of the absence of differences between the groups was regarded as significant at $p < 0.05$.

Results. The technical success of the operation amounted to 100% in both groups. There were no complications (such as haematoma, arterial dissection, etc.) in the area of the approach in either group. The findings of ultrasonographic examination of the extracranial portion of the carotid arteries demonstrated a significant difference in the form of a decrease in the degree of narrowing of the operated vessel ($p < 0.05$) as compared with its initial parameters. The number of the detected foci of acute cerebral ischaemia in the postoperative period (24–48 h) amounted to: in the Acculink group – 14 (56%), in the CGuard group – 12 (48%), $p > 0.77$. Of these, multiple foci in Group One were encountered significantly more often than in Group Two ($p = 0.02$). The patients with the Acculink stent implanted were found to develop 2 (4%) episodes of acute cerebral circulation impairment: the first one occurring after 24 hours and the second one at 28 days after stenting, with no such complications observed in Group Two patients.

Conclusion. Comparing the two stents (Acculink and CGuard) demonstrated no advantages with respect to safety and efficacy of either stent in endovascular treatment of patients with atherosclerotic lesions of brachiocephalic arteries.

Key words: carotid artery stenting, acute ischaemia foci.

INTRODUCTION

Haemodynamically significant stenoses of the internal carotid artery are encountered in 2 to 8% of the general population and remain a modifiable risk factor for the development of acute cerebral circulatory impairment [1–3]. An “open” operation, i. e. carotid endarterectomy (CEA), is considered the gold standard of treatment. However, endovascular procedures [stenting of the internal carotid artery (ICA)] currently occupy also a prominent place in angioplasty and may be recommended both with and without the use of temporary embolic protection devices [4, 5].

According to the findings of studies (during ICA stenting using both open – and closed-cell stents),

approximately 40–60% of adverse neurological events occur in the postoperative period when the temporary cerebral embolic protection device has already been removed [6–8]. Prolapse of the body of an atherosclerotic plaque (ATP) through the cell stent has been suggested as one of the major causes of post-procedural complications following carotid artery stenting [9–12].

Special devices have been created to decrease the incidence of plaque prolapse and cerebral microembolisms. One of such devices is the CGuard stent wrapped with an additional MicroNet mesh on the outside around the frame and designed to prevent peri- and postprocedural embolism. According to the findings of the CARENET and PARADIGM trials, in using

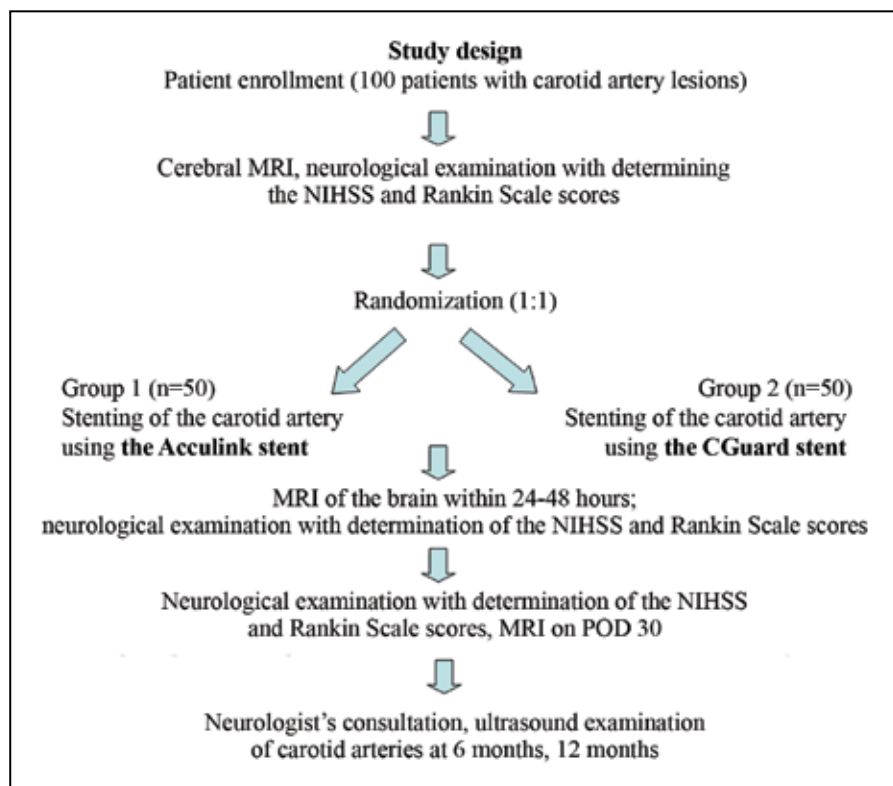


Fig. Schematic presentation of the study design. NIHSS (National Institutes of Health Stroke Scale); Rankin Scale (scale to assess functional outcomes in patients with endured stroke)

the CGuard stent the incidence of adverse cardiac or neurological events at 30 days of postoperative follow up equalled zero, thus suggesting its safety, with the results of diffusion-weighted magnetic resonance imaging (DW-MRI) of the brain demonstrating high efficacy of this device in terms of decreased incidence of new acute cerebral ischaemic lesions [13, 14].

Taking into consideration the absence of randomized studies aimed at comparing last-generation stents with open and closed cells, we formulated a hypothesis of the presented analysis: the CGuard stent should decrease the number of procedural and postprocedural foci of cerebral acute ischaemia according to the data of magnetic resonance imaging versus a comparison stent.

PATIENTS AND METHODS

The study was carried out as a prospective single-centre randomized trial (Figure). With due regard for the literature data and calculation of the power of the study we plan to include a total of 100 patients with haemodynamically significant ICA stenosis. The study was approved by the Local Ethics Committee of the NMRC named after E.N. Meshalkin under the RF Public Health Ministry (protocol № 7 dated May 26, 2017), as well as registered at ClinicalTrials.gov as NCT03488199. All documents are kept in accordance

with the Good Clinical Practice standard. Inclusion criteria were as follows: internal carotid artery (ICA) stenosis of more than 80% in an asymptomatic patient and ICA stenosis over 50% in a symptomatic patient. More detailed information concerning the inclusion criteria is available at the ClinicalTrials.gov Web site. Currently, our study has enrolled a total of 50 patients randomized into two groups in a 1:1 ratio. The groups were balanced by age, gender, and accompanying pathology (Table 1). Group One patients underwent stenting of the internal carotid artery using the CGuard stent, with Group Two patients receiving the Acculink stent.

The primary endpoint of the study: incidence of acute cerebral ischaemia foci according to MRI findings at 24–48 hours and on POD 30.

Secondary endpoints of the study: a) technical success of the intervention; b) periprocedural and 30-day minor stroke and transitory ischaemic attack; c) periprocedural or 30-day major adverse events.

The procedure of “carotid artery stenting” was performed in all patients according to the standard technique, medicamentous therapy prior to surgery and in the postoperative period did not differ between the groups and complied with the guidelines on managing patients presenting with brachiocephalic artery disease [15].

STATISTICAL DATA ANALYSIS

The data were accumulated and primarily sorted using the Microsoft Excel 2010 software programme. The obtained results were processed using the software package for statistical analysis “Statistica 13” (StatSoft Inc., USA). The quantitative data were expressed as the median (25th; 75th percentile), with the fractions expressed in percent. The normal distribution of the quantitative data was checked by means of the Shapiro–Wilk test. The normally distributed quantitative data were presented as the mean \pm standard deviation, abnormally distributed data were presented as the median with the 5 and 95% quantiles. The statistical significance of differences between the groups was determined with the help of the Mann–Whitney U test for quantitative data and with the help of the Fisher’s exact test

Baseline characteristics of patient groups				Table 1	
Variable		Group 1 Acculink n=25	Group 2 CGuard n=25	p	
age		66 [64;69]	66 [63;72]	0.66	
Gender	male	19 [76%]	16 [64%]	0.53	
	female	6 [24%]	9 [36%]		
Accompanying pathology and risk factors	ischaemic heart disease	15 [60%]	19 [76%]	0.36	
	chronic cardiac insufficiency	22 [88%]	22 [88%]	1	
	diabetes mellitus	5 [20%]	3 [12%]	0.70	
	percutaneous transluminal angioplasty of coronary arteries	8 [32%]	14 [56%]	0.15	
	percutaneous transluminal angioplasty of lower-limb arteries	5 [20%]	3 [12%]	0.70	
	aortofemoral bypass grafting	1 [4%]	1 [4%]	1.00	
	coronary artery bypass grafting	1 [4%]	4 [16%]	0.38	
	hypertensive disease	24 [96%]	24 [96%]	1	
	Smoking	7 [28%]	10 [40%]	0.55	
	hypercholesterolaemia	4 [16%]	1 [4%]	0.38	
	asymptomatic patients	20 [80%]	15 [60%]	0.21	
	symptomatic patients	5 [20%]	10 [40%]	0.21	
	acute impairment of cerebral circulation	3 [12%]	7 [28%]	0.28	
	transitory ischaemic attack	2 [8%]	3 [12%]	0.67	
neurological deficit (paresis, paralysis)	2 [8%]	3 [12%]	0.67		
Peculiarities of carotid artery lesion	stenosis degree	75 [70;79]	75 [70;81]	0.89	
	side of lesion	right ICA	13 [52%]	15 [60%]	0.77
		left ICA	12 [48%]	10 [40%]	0.77
	contralateral carotid artery lesion	3 [12%]	10 [40%]	0.05	
	previous interventions on the contralateral carotid artery	4 [16%]	2 [8%]	0.40	

for qualitative data. Intergroup analysis of dependent quantitative data was performed using the Wilcoxon signed-rank test and that of qualitative data by means of the McNemar's test. Differences were regarded as statistically significant if $p < 0.05$.

RESULTS

The success rate of surgical intervention amounted to 100% in both groups, with no complications (haematoma, arterial dissection, etc.) in the area of access revealed. However, mention should be made of an intraoperatively encountered significant technical peculiarity related to poor flexibility of the construction in the form of difficulty in delivering the open-cell stent (CGuard) to the stenosis zone.

The findings of ultrasonographic examination of brachiocephalic arteries demonstrated a significant difference in blood flow velocity before and after surgery in each group, thus also confirming success of the procedure (Table 2).

The findings of MRI at baseline revealed no foci of acute cerebral ischaemia. However, discirculatory-pattern foci corresponding to the age-related changes and/or a history of AICC were determined in one third of the patients.

Two (8%) symptomatic patients in the Acculink group were found to have neurological deficit (paresis/paralysis) prior to surgery, with 3 (12%) patients diagnosed as having this pathology in the CGuard group ($p \geq 0.05$).

During 30 days 48 (96%) patients demonstrated no alterations in the neurological status (as assessed by the NIHSS and Rankin Scale). Two (4%) Group One patients were found to have cerebral ischaemic stroke (reliably insignificant). One initially asymptomatic patient 24 hours after stenting of the coronary artery developed signs of mild neurological deficit in the ipsilateral basin, with a score of 1 by the NIHSS and Rankin Scale. The findings of the control ultrasonographic examination

demonstrated the stented carotid artery free from restenosis and haemodynamically significant stenosis. After 12-day restorative treatment the patient was discharged in a satisfactory condition. In the second case – AICC also occurred in an initially asymptomatic patient, however after 28 postoperative days. At examination, neurological deficit scored 4 points by the NIHSS and 1 point by the Rankin Scale. The stent in the carotid artery by the ultrasonographic examination was free from haemodynamically significant changes.

In the analysed groups there were no significant differences in the incidence and total volume of brain

Blood flow velocity by the findings of ultrasonographic diagnosis				Table 2
Period of study	CGuard group, n=25 [m/s]	Acculink group, n=25 [m/s]	p	
Before surgery	2.15 [1.6;3.92]	2.20 [1.73;3.00]	0.86	
After surgery	0.76 [0.61;0.83]	0.72 [0.6;0.9]	0.72	
p	<0.05	<0.05		

Table 3

Characteristics of parameters after surgery at in-hospital stage				
Variable		Group 1 Acculink, n=25	Group 2 CGuard, n=25	p
major adverse cardiovascular events (MACE)		2 (8%)	0	0.48
acute impairment of cerebral circulation		1 (4%)	0	1
myocardial infarction		1 (4%)	0	1
Ischaemic foci in patients	in asymptomatic patients	10 (50%)	7 (47%)	0.55
	in symptomatic patients	4 (80%)	5 (50%)	1
total number of cerebral ischaemia foci		14 (56%)	12 (48%)	0.77
Characteristics of the foci	singular	4 (17%)	8 (32%)	0.32
	multiple	10 (44%)	4 (16%)	0.02
total volume of cerebral ischaemia foci [mm]		5 [3,4;7]	4 [3;6.5]	0.26
Ischaemic foci size	no foci	11 (44%)	13 (52%)	0.77
	less than 3 mm	4 (16%)	6 (24%)	0.72
	3 mm and more	10 (40%)	6 (24%)	0.36
Foci localization:	ipsilateral	10 (40%)	10 (40%)	1
	contralateral	0	0	1
	bilateral	4 (16%)	2 (8%)	0.66
NIH Stroke Scale score	before	0 [0;0]	0 [0;0]	
	after	0 [0;0]	0 [0;0]	
Rankin Scale score	before	0 [0;0]	0 [0;0]	
	after	0 [0;0]	0 [0;0]	

Note: MACE - major adverse cardiovascular events (acute impairment of cerebral circulation, myocardial infarction, and patient's death).

lesions by the MRI findings 24–48 hours after surgical intervention. However, in the CGuard group there was a tendency towards detecting singular and smaller-size local foci as compared with the Acculink group patients. Mention should also be made that the location of ischaemic portions was identical in both groups (Table 3).

In the CGuard group, all detected foci of acute ischaemia at the in-hospital stage diminished by day 30 of follow up, with no new portions of lesion revealed. In the Acculink group, new foci of acute symptom-free ischaemia were detected in two cases. In one patient zones of lesion were revealed on control MRI by day 30 of follow up; the second patient besides the foci revealed 24 hours after surgery developed additional portions of acute cerebral ischaemia by POD 30 (Table 4).

DISCUSSION

The purpose of the present study was to compare the incidence of subclinical embolism of the brain depending on the stent type (open-cell vs. close-cell type) implanted into the carotid artery during endovascular treatment of patients.

The obtained findings demonstrated that the number of MRT-detected cerebral embolisms after stenting of ICA with Acculink and CGuard was similar. Therefore, there is no superiority of the design of the open-cell stent versus the closed-cell stent with respect to cerebral embolization. Besides, technical drawbacks of the closed-cell stent, complicating the course of the operation were shown within the time frame of the study.

Currently available on the market are two brands of “double-layer” stents: RoadSaver, Terumo/Casper, Microvention and CGuard, InspireMD. Apart from the differences in the nitinol frame design (braided closed cell in RoadSaver/Casper and open cell in CGuard) the two double-layered carotid stent systems have other important design differences. These include the position of the mesh in relation to the nitinol frame (outside the frame for the CGuard EPS and inside in the case of the RoadSaver/Casper) and the mesh material (braided nitinol in RoadSaver/Casper and PET single-fibre knitted MicroNET in CGuard) [16–23].

There are some articles reporting efficacy of the RoadSaver and Casper stents [17–23]. However, it should be mentioned that the RoadSaver stent (Terumo, Tokyo, Japan) is branded as Casper (Terumo, Saint-Germain-en-Laye, France), hence these stents are identical and the articles presented

hereinafter should be regarded as the results of using one stent under various trade names.

In their article, Machnic R. reported a retrospective assessment of 30-day safety and efficacy of a total of 41 procedures of internal and common carotid artery stenting procedures using the RoadSaver double nitinol layer micromesh in 40 non-consecutive patients with symptomatic or high-risk carotid artery stenosis. Proximal (n=27) or distal (n=14) embolic neuroprotection was used. The RoadSaver stents were implanted successfully in all cases. One minor stroke occurred after common carotid artery intubation with a guiding catheter (before stent deployment) and one transient postprocedural ischemic attack (TIA) of the ipsilateral cerebral hemisphere was observed. No other clinical complications were observed. Based on the above-mentioned findings, the researchers came to a conclusion that carotid artery stenting using the dual-layer RoadSaver nitinol stent was safe and effective [16]. Broussalis E. described their experience in treating a total of 110 patients with severe carotid artery stenosis (median degree of stenosis 80%, median length of stenosis 10 mm)

30-day period of follow up				Table 4
Variable		Group 1 Acculink, n=25	Group 2 CGuard, n=25	p
major adverse cardiovascular events (MACE)		0	1 (4%)	1
acute impairment of cerebral circulation		0	1 (4%)	1
myocardial infarction		0	0	1
total number of cerebral ischaemia foci		2 (8%)	0	0.48
total volume of cerebral ischaemia foci (mm)		0 (0;0)	6.5 (3;10)	0.63
Characteristics of the foci	singular	0	1 (4%)	1
	multiple	0	1 (4%)	1
Ischaemic foci size	less than 3 mm	0	1 (4%)	1
	3 mm and more	0	1 (4%)	1
Foci localization:	ipsilateral	0	1 (4%)	1
	contralateral	0	0	1
	bilateral	0	1 (4%)	1
NIH Stroke Scale score		0 (0;0)	0 (0;0)	0.71
Rankin Scale score		0 (0;0)	0 (0;0)	1
blood flow velocity (m/s) at ultrasonographic examination		0.61 (0.54;0.71)	0.68 (0.56;0.84)	0.17

with the help of implantation of the Casper stent. Postprocedurally, 7.3% (8/110) of patients were found to have ischemic DW-MRI lesions. They were all “silent foci of acute cerebral ischaemia”, i. e. were free from clinical manifestations [21]. The results suggesting efficacy and safety of RoadSaver/Casper stents were also reported in the article by Ruffino M.A., where the incidence of acute ischaemia foci by the findings of DWI 24 hours after stenting amounted to 30.4% [22]. In their articles Nerla R. and Orlando D. reported neither strokes nor TIAs during the in-hospital period and 30 days postoperatively [17, 23]. Considering the hereinabove studies, mention should be made of a series of limitations: the results of retrospective data, patients not in all cases were subjected to MRI before and after ICA stenting.

One of the recently introduced and acceptable devices is the double-layer stent CGuard [1, 2, 10, 13]. Its efficiency and safety were evaluated in several cohort studies. Thus, in the CARENET trial the CGuard stent was successfully implanted in 30 patients. New ipsilateral ischemic lesions at 48 h occurred in 37.0% of patients and the average lesion volume was 0.04 cm³, thus indicating a ~2-fold reduction in the prevalence of any DW-MRI lesion(s) and over 10-fold reduction in mean lesion volume when CGuard EPS rather than a conventional carotid stent is used. The 30-day diffusion-weighted magnetic resonance imaging showed one new acute ischaemia lesion (0.08 cm³) and complete resolution of all but 1 periprocedural lesion [14].

We for the first time in the world made an attempt to assess two types of stents in a randomized study officially entitled the SIBERIA trial and aimed at comparing widely used in clinical practice Acculink and CGuard stents [24]. Taking into consideration that the additional mesh on the struts of the CGuard stent contains 150-µm pores, we used as a protecting device in all patients the Emboshield trap whose filter diameter is also 150 µm. Based on the interim results of this trial, in both groups of stents (Acculink and CGuard) we revealed an inconsiderable number of bilateral and contralateral lesions of the brain, with the incidence of cerebral embolization being similar in both groups as determined by the findings of diffusion-weighted magnetic resonance imaging.

CONCLUSION

Analysing the obtained results of the randomized study of the two stents (open-cell and closed-cell types) did not show advantage of either device in endovascular treatment of patients with haemodynamically significant lesions of the internal carotid artery.

Conflict of interest: none declared.

ЛИТЕРАТУРА/REFERENCES

- Mazzaccaro D., Occhiuto Maria T., Righini P., et al.** Initial experience with the inspire MD C-Guard stent in the treatment of carotid artery disease. *Cardiovasc. Surg.* (Torino). 2016; 57: 3: 474–478.
- Mozaffarian D., Benjamin Emelia J., Go Alan S., et al.** Heart Disease and Stroke Statistics–2016 Update: A report from the American Heart Association. *Circulation.* 2016; 133: 38–60.
- O'Brien M., Chandra A.** Carotid revascularization: risks and benefits. *Vasc. Health. Risk. Manag.* 2014; 10: 403–416.
- Kinlay S.** Fire in the hole: carotid stenting versus endarterectomy. *Circulation.* 2011; 123: 2522–2525.
- Brooks W., McClure Rick R., Jones Michael R., et al.** Carotid angioplasty and stenting versus carotid endarterectomy: randomized trial in a community hospital. *J. Am. Coll. Cardiol.* 2001; 38: 1589–1595.
- Fairman R., Gray W.A., Scicli A.P., et al.** The CAPTURE registry: analysis of strokes resulting from carotid artery stenting in the post approval setting: timing, location, severity, and type. *Ann. Surg.* 2007; 246: 551–556.
- Bosiers M., de Donato G., Deloose K., et al.** Does free cell area influence the outcome in carotid artery stent-

- ing? Eur. J. Vasc. Endovasc. Surg. 2007; 33: 135–141.
8. **Hill M.D., Brooks W., Mackey A., et al.** Stroke after carotid stenting and endarterectomy in the Carotid Revascularization Endarterectomy versus Stenting Trial (CREST). *Circulation*. 2012; 126: 3054–3061.
 9. **Reimers B., Nikas D., Stabile E., et al.** Preliminary experience with optical coherence tomography imaging to evaluate carotid artery stents: Safety, feasibility, and techniques. *EuroIntervention*. 2011; 7: 98–105.
 10. **De Donato Gianmarco M., Setacci Francesco., Sirignano Pasqualino., et al.** Optical coherence tomography after carotid stenting: Rate of stent malapposition, plaque prolapse and fibrous cap rupture according to stent design. *Eur. J. Vasc. Endovasc. Surg.* 2013; 45: 579–587.
 11. **Liu Rui., Jiang Y., Xiong Y., et al.** An optical coherence tomography assessment of stent strut apposition based on the presence of lipid-rich plaque in the carotid artery. *J. Endovasc. Ther.* 2015; 22: 942–949.
 12. **De Donato Gianmarco M., Smith A., Potter C.** Optical coherence tomography after carotid stenting: subsequent analysis. *Eur. J. Vasc. Endovasc. Surg.* 2015; 41: 600–610.
 13. **Musialek P., Mazurek A., Trystula M., et al.** Novel PARADIGM in carotid revascularisation: Prospective evaluation of all-comer percutaneous carotid revascularisation in symptomatic and increased-risk asymptomatic carotid artery stenosis using CGuard™ MicroNet-covered embolic prevention stent system. *EuroIntervention*. 2016; 12: 658–670.
 14. **Schofer J., Musialek P., Bijuklic K., et al.** A prospective, multicenter study of a novel mesh-covered carotid stent: The CGuard™ CARENET trial (Carotid Embolic Protection Using MicroNet). *JACC Cardiovasc. Interv.* 2015; 8: 1229–1234.
 15. **Aleksyan B.G., Abrosimov A.V., Aivazyan G.G. et al.** Roentgen Endovascular Surgery. National Guide: in 4 volumes. Moscow, Litterra Publishing House. 2017 (in Russian).
 16. **Machnik R., Paluszek P., Tekieli Ł., et al.** Mesh-covered (Roadsaver) stent as a new treatment modality for symptomatic or high-risk carotid stenosis. *Postepy Kardiol. Interwencyjne*. 2017; 13: 2: 130–134.
 17. **Orlando D., Gloria L., John O.F., Roehm Jr., et al.** The Casper carotid artery stent: A unique all metal micromesh stent designed to prevent embolic release. *J. Neurointervent. Surg.* 10: 2: 133–136; doi:10.1136/neurintsurg-2016-012913 .
 18. **Musialek P., Hopkins L. Nelson and Siddiqui Adnan H.** One swallow does not a summer make but many swallows do: accumulating clinical evidence for nearly-eliminated peri-procedural and 30-day complications with mesh-covered stents transforms the carotid revascularisation field. *Postepy Kardiol. Interwencyjne*. 2017; 13: 2: 95–106.
 19. **Wisgott C., Schmidt W., Brandt-Wunderlich C., et al.** Clinical Results and Mechanical Properties of the Carotid CGUARD Double-Layered Embolic Prevention Stent. *J. Endovasc. Ther.* 2017; 24: 1: 130–137.
 20. **Wisgott C., Schmidt W., Brandt-Wunderlich C., et al.** Preliminary clinical results and mechanical behavior of a new double-layer carotid stent. *J. Endovasc. Ther.* 2015; 22: 634–639.
 21. **Broussalis E., Griessenauer C., Mutzenbach S., et al.** Reduction of cerebral DWI lesion burden after carotid artery stenting using the CASPER stent system. *J. NeuroIntervent. Surg.* 2018; 11:1: 62–67.
 22. **Ruffino M.A., Faletti R., Bergamasco L., et al.** Incidence of New Ischaemic Brain Lesions After Carotid Artery Stenting with the Micromesh Roadsaver Carotid Artery Stent: A Prospective Single-Centre Study. *Cardiovasc. Intervent. Radiol.* 2016; 39: 11: 1541–154.
 23. **Nerla R., Castriota F., Micari A., et al.** Carotid artery stenting with a new-generation double-mesh stent in three high-volume Italian centres: clinical results of a multidisciplinary approach. *Euro. Intervention*. 2016; 12: 5: 677–683.
 24. **Kazantsev A.N., Burkov N.N., Tarasov R.S. et al.** Carotid endarterectomy in acute period of ischaemic stroke. *Circulation Pathology and Cardiac Surgery*. 2018; 22: 1: 66–72 (in Russian).