

RESULTS OF ENDOVASCULAR TREATMENT OF OBSTRUCTIVE LESIONS OF VEINS OF THE ILIOFEMORAL SEGMENT

POKROVSKY A.V.^{1,2}, IGNATYEV I.M.^{3,4}, GRADUSOV E.G.²

¹ Institute of Surgery named after A.V. Vishnevsky under the RF Ministry of Public Health,

² Russian Medical Academy of Continuous Professional Education under the RF Ministry of Public Health, Moscow,

³ Interregional Clinical Diagnostic Centre,

⁴ Kazan State Medical University of the RF Ministry of Public Health, Kazan, Russia

Objective. The purpose of the study was to assess the immediate and remote results of endovascular treatment of obstructive lesions of the veins of the iliofemoral segment.

Patients and methods. We performed balloon angioplasty and stenting for iliofemoral venous thrombosis in a total of 75 patients. Of these, 60 patients were subjected to stenting of post-thrombotic obstructions and 15 patients underwent stenting of non-thrombotic obstructive lesions of the iliac veins (for May–Thurner syndrome – in 11, for extravasal tumour-induced compression and cicatricial stenosis – in 4).

Stenting was performed using self-expanding stents Wallstent (Boston Scientific, n=84) or S.M.A.R.T. (Cordis, Johnson & Johnson, n=16). The stent diameter varied from 12 to 18 mm depending on the venous segment to be stented. The average number of the implanted stents amounted to 1.3 per patient. Efficacy of endovascular intervention was evaluated by measuring the pressure gradient and malleolar circumference. The clinical result was determined by the Venous Clinical Severity Score (VCSS).

Results. Technical success of endovascular intervention amounted to 92%. Stent thrombosis in the immediate postoperative period occurred in 7 (9.3%) patients. Of these, three patients were subjected to catheter-directed thrombolysis with restoration of patency of the stented venous segment of the limb. Stent occlusion within 48 postoperative months was diagnosed in 4 cases. Two patients underwent successful repeat angioplasty and stenting. Stent restenosis of not less than 50% at 36 months of follow up was observed in 5 (16%) patients. Repeat stenting was performed in 1 case. Dynamic control of stent patency was carried out by means of ultrasound duplex scanning. Also performed were control multislice computed tomography–phlebography and roentgen contrast phlebography. Cumulative primary and secondary patency at 60 months in post-thrombotic lesions amounted to 72 and 81%, respectively, in non-thrombotic lesions to 85% (primary patency). The VCSS values demonstrated a significant decrease in manifestations of chronic venous insufficiency. The mean value of the composite parameter decreased from 14.2 ± 4.2 to 7.5 ± 2.6 ($p < 0.001$), the malleolar circumference decreased from 272.3 ± 6.7 to 250.6 ± 6.1 mm ($p < 0.01$). Permanent healing of trophic ulcers was noted in 5 (71%) patients.

Conclusion. The method of endovascular angioplasty and stenting for obstructive lesions of the veins of the iliofemoral segment is a minimally invasive, safe, and highly effective therapeutic modality, which is confirmed by significant improvement of the limb's condition and good remote results of patency of the venous segments restored. Endovascular methods should be wider implemented into the clinical practice.

Key words: obstructive lesions of iliac veins, balloon angioplasty and stenting, duplex scanning, magnetic resonance and computed phlebography, contrast phlebography.

INTRODUCTION

Percutaneous endovenous stenting has over the last decade emerged as a method of choice in treatment for obstructive lesions of the veins of the iliofemoral segment and of the inferior vena cava. Efficacy of endovascular procedures has been confirmed in many studies [1–3]. The American Venous Forum recommends venous angioplasty and stenting in treatment of symptomatic patients (with CEAP clinical class C3–C6) with chronic occlusions or pronounced stenoses of the inferior vena cava or iliac

veins (with or without reflux along the deep veins) together with standard compression therapy (1B-level recommendations and evidence) [4].

Popularity of this endovascular technique has substantially increased in recent years due to implementation of new methods of visualisation into clinical practice, the appearance of modern-generation venous stents, high efficacy and reliable remote results. Overall cumulative primary, assisted primary, and secondary patency rates up to 72 months have been reported as 67 to 80%, 76 to 88%, and 90 to 93%,

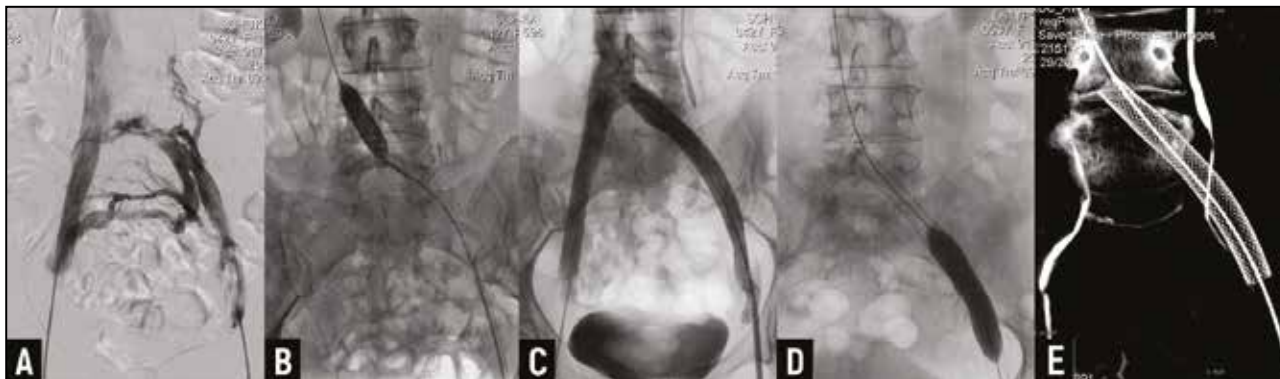

Fig. 1. Stages of balloon dilation and stenting of occlusion of the left common iliac vein (A-E) (see the text for explanation)

respectively, being accompanied and followed by a low complication rate [5, 6]. Nevertheless, in total occlusion of iliac veins and the inferior vena cava, primary patency at 60 months amounts to approximately 50 % [7].

By now, more than 5,000 stenting procedures have been performed worldwide for chronic deep-vein obstruction, with the follow-up duration varying from several months to 10 years. Primary and secondary stent patency ranged from 33 to 98.7% and from 66 to 100% respectively [8].

Our study was undertaken to evaluate both the immediate and remote results of endovascular treatment for obstructive lesions of the veins of the iliofemoral segment.

PATIENTS AND METHODS

Between February 2009 and March 2017, balloon angioplasty and stenting for the treatment of obstructive lesions of the veins of the ilio-femoral segment were performed in a total of seventy-five 17-to-63-year-old patients (43 men and 32 women). Of these, stenting of post-thrombotic obstructions was carried out in 60 patients and stenting of non-thrombotic obstruction of the iliac veins in 15 patients (for May-Thurner syndrome – in 11 and for tumour-induced extravasal compression and cicatricial stenosis after radiotherapy – in 4). The distribution of the patients according to the CEAP classification was as follows: C3,S – in 12, C4a – in 24, C4b – in 32 and C6 – in 6). Hybrid operations (open + endovascular) were performed in 13 patients, with their results published previously [9].

Preliminary diagnosis of obstructive lesions of the iliofemoral segment was carried out with the help of ultrasound duplex scanning (USDS), multislice computed tomography (CT) phlebography or magnetic resonance phlebography. The indications for stenting were specified by performing contrast phlebography.

All patients were examined for detecting thrombophilia markers: C and S proteins, antithrombin III, factor V Leiden mutation, prothrombin G20210A gene mutation, antiphospholipid antibodies, homocysteine level, as well as determining the D-dimer value.

While determining the indications for stenting, especially in stenotic lesions of the iliac veins, we performed direct phlebomanometry with measuring the pressure gradient in the portions distal and proximal to stenosis. In the course of carrying out phlebomanometry the revealed gradients of intravenous pressure varied ranging from 1 to 24 mm Hg. The average pressure gradient amounted to 8.2 ± 1.2 mm Hg. Haemodynamically significant was considered

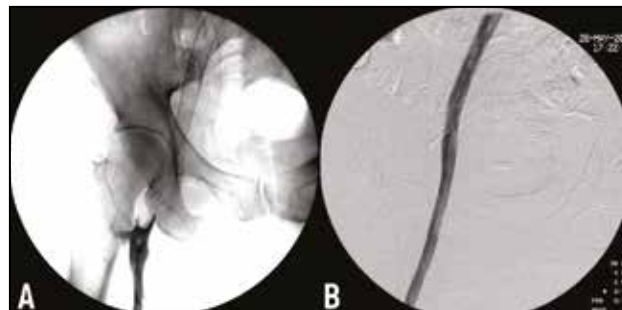


Fig. 2. Thrombosed stent of the common and external iliac veins (A). Restoration of stent patency after thrombolysis (B)

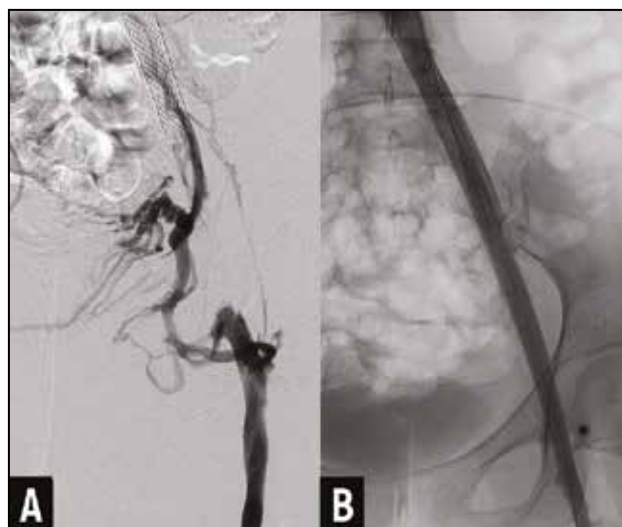

Fig. 3. Occlusion of the stent of the external and common iliac veins (A). Re-stenting at 5 months after surgery with the stent patency restored (B)

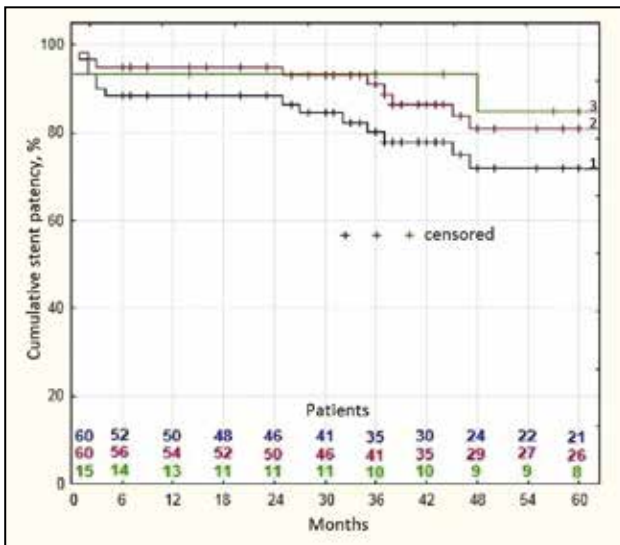


Fig. 4. Cumulative primary and secondary stent patency: 1 – primary patency; 2 – secondary patency; 3 – patency in non-thrombotic lesions

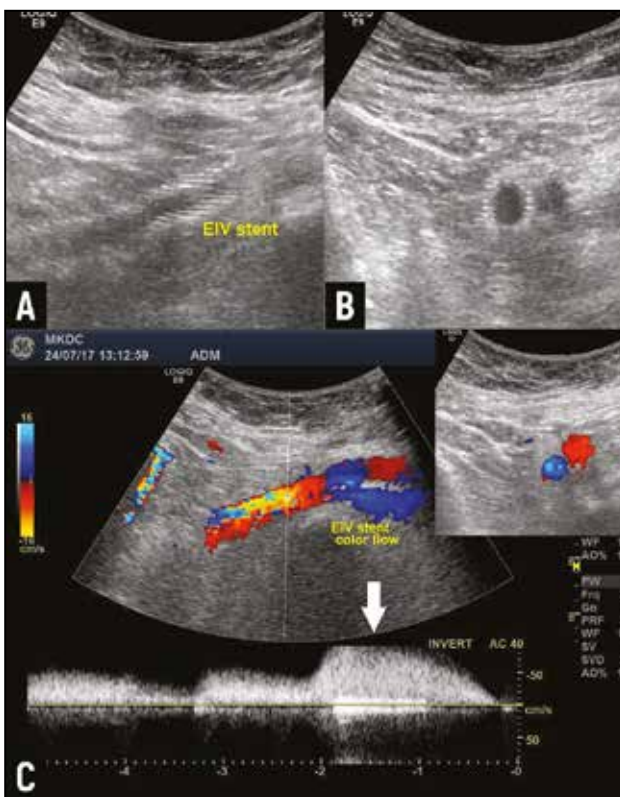


Fig. 5. Echograms of the stent of the external iliac vein (EIV) in the B-mode: longitudinal (A) and transversal (B) projections; in the mode of CDM (longitudinal and transversal projections) and spectral Doppler (C). The stent is free from evidence of deformity or stenosis, being patent. Seen of the Dopplerogram is phasic blood flow, increasing on distal manual compression (arrow)

obstruction at which the pressure gradient was not less than 4 mm Hg.

Carrying out the procedure was accompanied by administering non-fractionated heparin whose doses were controlled with the help of the activated clotting

time (ACT). Heparinization was considered adequate at the ACT values within 250–300 s.

Endovascular interventions were carried out under either local (in non-thrombotic obstruction) or general (in stenting of extended occlusive lesions and hybrid operations) anaesthesia. Both transfemoral and transpopliteal ultrasound-guided approaches were used.

We performed multiplane phlebography and carried out the standard procedure of recanalization of the iliofemoral segment with soft (in stenosis) or rigid (in occlusion) hydrophilic 0.035-inch guidewires (Terumo Medical) (Fig. 1, A) and a series of predilatations with balloon catheters (Mustang, Boston Scientific; Atlas, Bard) (Fig. 1, B). For stenting, we used self-expanding stents Wallstent-Uni Endoprosthesis (Boston Scientific, Natick, MA, USA) (n=84) or S.M.A.R.T. (Cordis, Johnson & Johnson, New Brunswick, NJ, USA) (n=16). The stent diameter varied from 12 to 18 mm (depending on the venous segment to be stented), with the length ranging from 60 to 90 mm. Three patients received nitinol stents manufactured by the «MIT» Ltd. (Russia). The average number of the implanted stents, depending on the character and length of obstructive lesions, amounted to 1.3 (from 1 to 6) per patient.

Stent deployment was followed by control phlebography and post-dilatation with the balloons of the appropriate diameters (Fig. 1, C, D). We then performed three-dimensional rotational x-ray of the stent in order to assess adequacy of its placement (Fig. 1, E).

After a successful procedure of stenting, the pressure gradient amounted to 1.3 ± 0.7 mm Hg, which was significantly less ($p < 0.01$) than the mean value of the pressure gradient prior to endovascular intervention.

The patients started ambulation 6 hours after surgery, with elastic bandages applied. Intermittent pneumatic compression of the lower limbs was an obligatory component of postoperative treatment delivered via a Flowpac pump (Huntleigh Healthcare, Cardiff, Great Britain). Low-molecular-weight heparins (enoxaparin sodium, nadroparin calcium) were administered in therapeutic doses for 3 to 5 days, followed by switching to either warfarin (monitored by the international normalised ratio, target values: 2.0–3.0) or to new oral anticoagulants (rivaroxaban 20 mg daily) for 6 months in a combination with drugs containing acetylsalicylic acid or clopidogrel (plavix) at a dose of 75 mg. Various regimens of anticoagulant treatment were used within the timeframe of the study.

The data was statistically processed with the help of the software package “Statistica 10” (StatSoft, Inc., USA) with the use of the Wilcoxon signed-rank test. Results were regarded as statistically significant if $p < 0.05$. Cumulative stent patency was assessed with the help of the Kaplan–Mayer curves.

RESULTS

In 6 patients, the procedure of stenting was unsuccessful due to an extended occlusive lesion of the iliac veins, with the technical success rate thus amounting to 92%. Of these, two patients were subjected to the operation of cross-over autovenous bypass grafting with the formation a distal arteriovenous fistula (AVF).

Stent patency was controlled with the help of USDS, contrast phlebography and CT phlebography.

Stent thrombosis in the immediate postoperative period occurred in 7 (9.3%) patients. Of these, 4 patients developed thrombosis of the stents deployed distal to the inguinal ligament. Three patients underwent successful catheter-directed thrombolysis with “Actilyse” (Boehringer Ingelheim Pharma, Germany) according to the standard treatment regimen, with the stent patency eventually restored (Fig. 2, A, B). One patient was found to have stasis of the radiopaque medium after stent placement, which was an indirect sign of poor inflow from the femoral veins. An operation of creating a proximal AVF between the superficial femoral artery and common femoral vein (CFV) was performed. The findings of dynamic follow up in both the immediate and remote periods demonstrated that the implanted stent proved patent, with a good clinical outcome obtained.

Stent restenosis of not less than 50% at 36 months was encountered in 5 (16%) patients. Successful restenting was performed in 1 case. Stent occlusion within 48 postoperative months occurred in 4 cases. Two patients underwent repeat angioplasty and stenting (Fig. 3, A, B).

Cumulative primary and secondary patency at 60 months after treatment for post-thrombotic obstructions amounted to 72 and 81%, respectively, with the primary patency after treatment of non-thrombotic venous lesions equalling 85% (Fig. 4).

USDS demonstrated high informative value in assessment of stent patency. Studying in the D-mode in the longitudinal and transverse projections makes it possible to determine the stent’s condition (no deformity or compression); in the mode of colour Doppler mapping (CDM) – patency of the stented segment; this was also evidenced by the presence of phasic, respiration-synchronized blood flow on the Dopplerogram, with blood-flow enhancement proximal to the stent in distal compression (Fig. 5. A–C).

More detailed information was provided by contrast phlebography or CT phlebography (Fig. 6, A, B; Fig. 7, A, B).

The VCSS (assessment at 36 months in 24 patients) showed a statistically significant decrease of intensity of manifestations

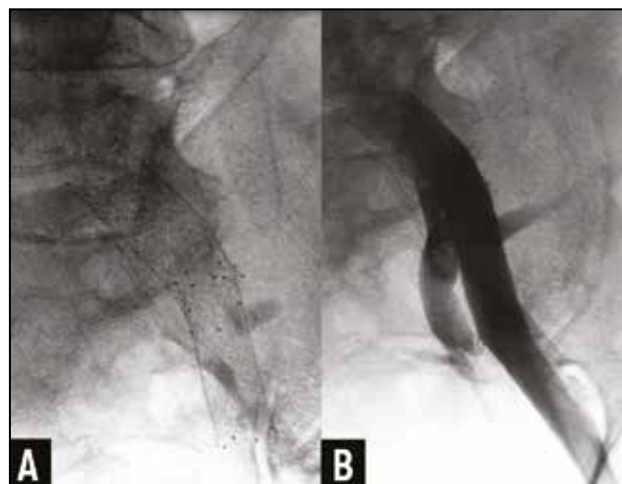


Fig. 6. X-ray (A) of the stent of the external iliac vein and phlebogram (B) at 4 years after stenting. The stent is freely patent

of venous insufficiency. The average value of the cumulative parameter decreased from 14.2 ± 4.2 to 7.5 ± 2.6 ($p < 0.001$). The malleolar circumference decreased from 272.3 ± 6.7 to 250.6 ± 6.1 mm ($p < 0.01$). Permanent healing of trophic ulcers was observed in 5 (71%) of 7 patients followed up with open ulcers prior to the endovascular operation.

DISCUSSION

Safety of recanalization, balloon angioplasty and stenting for chronic obstruction of deep veins has been proved by the experience of many centres during two decades [8]. In the majority of studies it was demonstrated that endovascular treatment was free from risk of lethality, pulmonary embolism or major haemorrhage [10].

Immediate-term stent thrombosis is encountered in 5–10% of cases [3, 6]. Stent patency may be restored by means of pharmacomechanical or catheter-directed thrombolysis, open thrombectomy with creation of an AVF and balloon angioplasty [6, 11].

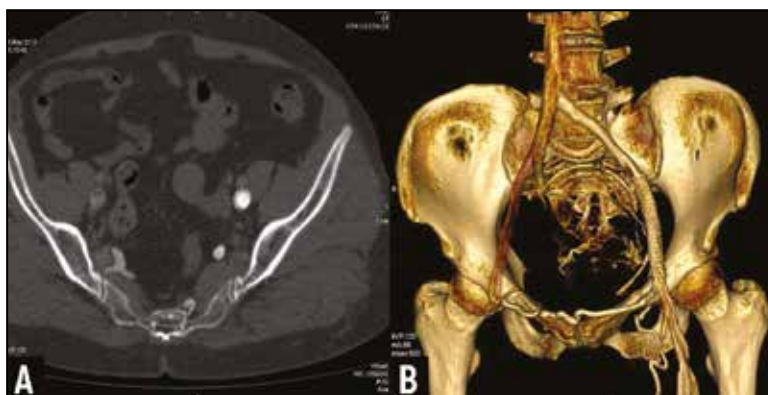


Fig. 7. Contrast-enhanced CT phlebography of the external iliac vein at 2 years after stenting; A - axial projection; B - 3D reconstruction. The stent is with no evidence of deformity, being patent

According to the findings of P. Saha, et al. [12], about 30% of patients require repeat endovascular intervention for stent occlusion. Most often, it occurs within the first 56 days after the primary intervention. At the same time, some specialists note a low incidence rate (4–6%) of thrombotic stent occlusions during the mid-term and long-term follow up after endovascular interventions [13, 14].

Long-term moderate-severity in-stent restenoses (ISR) are encountered rather commonly, but considerable narrowing of the stents' lumen (not less than 50%) at 72 months are observed in approximately 10–17% of patients with post-thrombotic syndrome [6]. About 25% of the stents require reinterventions to correct ISR/stent compression [11]. Causes of restenosis or occlusions of stents remain insufficiently clear. They are associated with either previously endured or relapsing thrombosis, neointimal hyperplasia, stenting of prolonged occlusive lesions involving the CFV [15].

The problem of restoration of patency in occlusion and pronounced in-stent restenosis is in many cases solved with the help of repeat angioplasty and stenting, sometimes performed several times, which namely determines rather high frequency of secondary stent patency [16]. The latter is substantially higher in stenting of non-thrombotic lesions of the iliac veins [3], which is also confirmed by the results of our study.

The cumulative rate of no relapses of trophic ulcers at 5 years amounts to 75–88%, with that of total relief of pain and oedemas amounting to 62–71% and 32–36%, respectively [17]. Clinical improvement was confirmed by positive dynamics by the scales of VCSS and Villalta [18].

Currently, there are neither randomized studies nor well-defined international guidelines, which would allow finding a “universal language” in the strategy of treating deep vein obstruction, thus making it impossible to compare the results of treatment of patients with this pathology in various centres [8]. From the literature data cited above it follows that in spite of considerable progress in endovascular technologies of treating patients with deep vein obstructive lesions unsolved as yet still remain problems requiring further studies.

CONCLUSION

Endovascular angioplasty and stenting for obstructive lesions of the veins of the iliofemoral segment is a minimally invasive, safe and highly efficient therapeutic modality, which was confirmed by considerable improvement of the extremity's state and good remote results of patency of the venous segments restored. Endovascular methods of treatment should be wider implemented into the clinical practice and may be considered as a method of choice in treatment of this cohort of patients.

Conflict of interest: none declared.

ЛИТЕРАТУРА/REFERENCES

1. **Neglén P.** Chronic deep venous obstruction: definition, prevalence, diagnosis, management. *Phlebology.* 2008; 23: 149–157.
2. **De Graaf R., Arnoldussen C., Wittens C.H.A.** Stenting for chronic venous obstructions a new era. *Phlebology.* 2013; 28(Suppl 1): 117–122.
3. **Neglén P.** Endovascular reconstruction for chronic iliofemoral vein obstruction. In: Gloviczki P., ed. *Handbook of Venous Disorders.* Third edition. London: Hodder Arnold; 2009; 491–502.
4. **Murphy E.H., Raju S.** Endovascular treatment of post-thrombotic iliofemoral venous obstruction. In: Gloviczki P., ed. *Handbook of Venous and Lymphatic Disorders.* Fourth edition. Boca Raton, FL: CRC Press; 2017; 533–539.
5. **Raju S., Darcey R., Neglén P.** Unexpected major role for venous stenting in deep reflux disease. *J. Vasc. Surg.* 2010; 51(2): 401–409.
6. **Hartung O., Otero A., Boufi M., et al.** Mid-term results of endovascular treatment for symptomatic chronic nonmalignant ilio caval venous occlusive disease. *J. Vasc. Surg.* 2005; 42: 6: 1138–1144.
7. **Murphy E.H., Johns B., Varney B., Raju S.** Endovascular management of chronic total occlusions of the vena cava and iliac veins. *J. Vasc. Surg.: Venous and Lym. Dis.* 2017; 5(1): 47–59.
8. **De Graaf R.** Management and treatment of occluded large veins. *Endovascular management.* In: Bækgaard N., Fanelli F., O'Sullivan G.J., eds. *New horizons in deep venous disease management.* Turin: Edizioni Minerva Medica; 2017; 160–171.
9. **Pokrovsky A., Ignatyev I., Gradusov E.** First experience of performing hybrid operations in chronic venous obstructions of iliofemoral segments in patients with post-thrombotic syndrome. *Vasc. Endovasc. Surg.* 2017; 5(7): 447–452.
10. **Mussa F.F., Peden E.K., Zhou W., et al.** Iliac vein stenting for chronic venous insufficiency. *Tex. Heart Inst. J.* 2007; 34: 60–66.
11. **Raju S., Tackett P., Neglén P.** Reinterventions for non-occlusive iliofemoral venous stent malfunctions. *J. Vasc. Surg.* 2009; 49(2): 511–518.
12. **Saha P., Karunanithy N., Breen K., et al.** One-year outcomes following deep venous reconstruction for thrombotic disease using dedicated endovenous stents. In: *Book of abstracts 16th Meeting of the European Venous Forum, 2–4 July, 2015 St. Petersburg, Russia;* 29.
13. **Neglén P., Raju S.** Balloon dilation and stenting of chronic iliac vein obstruction: technical aspects and early clinical outcome. *J. Endovasc. Ther.* 2000; 7: 79–91.
14. **Hartung O., Loundou A.D., Bartelemy P., et al.** Endovascular management of chronic disabling ilio-caval obstructive lesions: long-term results. *Eur. J. Vasc. Endovasc. Surg.* 2009; 38: 118–124.

15. **Wang Wenda., Zhao Yu., Chen Yue-xin.** Stenting for chronic obstructive venous disease: A current comprehensive meta-analysis and systematic review. *Phlebology.* 2016; 31(6): 376–389.
16. **Van Vuuren T.M.A.J., de Wolf M.A.F., Arnoldussen C.W.K.P., et al.** Editor's Choice – Reconstruction of the femoro-ilio-caval outflow by percutaneous and hybrid interventions in symptomatic deep venous obstruction. *Eur. J. Vasc. Endovasc. Surg.* 2017; 54(4): 495–503.
17. **Alerany B., Izquierdo L., Ramirez O., et al.** Endovascular treatment of iliofemoral chronic post-thrombotic venous flow obstruction. *J. Vasc. Surg.: Venous and Lym. Dis.* 2014; 2: 2–7.
18. **Sarici I.S., Yanar F., Agsaoglu O., et al.** Our early experience with iliofemoral stenting in patients with post-thrombotic syndrome. *Phlebology.* 2014; 29(5): 298–303.

Адрес для корреспонденции:
Игнатъев И.М.
Тел.: +7 (903) 341–47-37
E-mail: imignatiev@rambler.ru

Correspondence to:
Ignatyev I.M.
Tel.: + 7 (903) 341–47-37
E-mail: imignatiev@rambler.ru