

HYBRID SURGERY IN CHRONIC THORACOABDOMINAL AORTIC DISSECTION

CHERNYAVSKY A.M.¹, SIROTA D.A.¹, CAUS T.², KHVAN D.S.¹, ALSOV S.A.¹, LYASHENKO M.M.¹

¹ Novosibirsk Scientific Research Institute for Circulatory Pathology named after Academician E.N. Meshalkin, Novosibirsk, Russia

² Centre hospitalier universitaire d'amiens-picardie, 80054 Amiens Cedex 1, France

The authors describe and analyse their experience gained in performing prosthetic repair of the thoracoabdominal portion of the aorta, combined with open aortic stenting using the Djumbodis uncovered metal stent. Over the period from 2013 to 2015 we performed a total of 16 hybrid interventions. All patients were found to have type B aortic dissection, with their false and true lumens patent. All patients underwent reconstruction of the thoracoabdominal aorta combined with open implantation of the Djumbodis uncovered metal stent into the area of lower thoracic and visceral arteries. The patients underwent either isolated prosthetic repair of the thoracic aortic portion – type A correction, or prosthetic repair of the thoracic and infrarenal portions – type B correction. In the postoperative period we performed MSCT angiography of the thoracic and abdominal aortic portions in order to control patency of the true and false lumens, patency of visceral arteries, to assess the diameter of the aorta, presence or absence of thrombosis. All five patients subjected to type B correction (100% of the total number of this type operation) were found to develop thrombosis of the false lumen, and eight patients undergoing type A correction (72.7% of the total number of operations of this type) were diagnosed with false channel thrombosis. There was 1 (6.3%) lethal case registered at the hospital stage in the group of patients with type A correction. There were no cases of neurological deficit, malperfusion of visceral organs or lower-limb ischaemia. Our experience shows that using hybrid technologies in surgery of the thoracoabdominal portion of the aorta is (appears to be) optimal from the point of view of decreasing intraoperative trauma, reducing the complications rate and without detriment to the radicality.

Key words: aortic dissection, stenting of the aorta, uncoated metal stent.

INTRODUCTION

Aortic dissection continues to remain the most serious problem of modern cardiac surgery [1]. Intervention on the descending thoracic portion (in type B dissection or postoperative type A dissection) is, as a rule, performed in the remote period when there arise indications for the operation, including chronic pain, a rapidly growing false lumen, the diameter exceeding 55 mm and evidence of threatened rupture or impairment of distal perfusion [2, 3]. However, even with no complications, the long-term prognosis is not favourable and the mortality rate with false lumen patency preserved amounts to 20–40% during 3 years, in spite of medicamentous treatment and outpatient follow up [4–7]. Prosthetic repair of the thoracoabdominal aortic portion according to the classic technique suggested by Crawford is conjugated with a great number of such complications as perioperative haemorrhage, myocardial infarction, stroke of the brain, spinal cord, impaired perfusion of visceral organs and kidneys [8, 9]. Such

number of complications is associated a wide traumatic approach, great extension of the repaired portion of the aorta, a large number of reimplemented arteries and, accordingly, anastomoses, and, as a consequence, the duration of the operation. Total endoprosthetic repair of the aorta in the thoracoabdominal portion is not always possible because of a narrow true lumen occupying less than 20% as well as owing to difficulties while creating and implanting custom-made stent grafts [3, 10–12]. However, transferring to minimally invasive technologies helped develop alternative hybrid methods of reconstruction of aortic dissections, making it possible to perform total reconstruction of the thoracoabdominal aortic portion, simultaneously decreasing the scope of intraoperative injury at the expense of decreasing the number of anastomoses performed and reducing the time of ischaemia of visceral organs. Minimizing the approach in this case is a key moment for improving survival in the immediate postoperative period, while completeness of reconstruction makes it possible

to decrease the complication rate and frequency of relapses in the remote period [13]. Using hybrid technologies makes it possible to diminish surgical injury and decrease the complications rate in surgical management of aortic diseases [14].

PATIENTS AND METHODS

From August 2013 to May 2015, a total of 16 hybrid interventions on the thoracoabdominal portion of the aorta using Djumbodis uncoated metal stents were performed. The main indication for the intervention was the presence of type B chronic dissection with dilatation of the aortic diameter in the thoracoabdominal portion exceeding 5.5 cm. Besides, indications for the operation were as follows: rapid growth of the aneurysm (more than 0.5 cm during 6 months), as well as clinical symptoms (pain, dysphagia, and breathlessness). All patients had their true and false lumens patent. The Borst's procedure had preliminarily been performed in 4 (25%) patients. Patients presenting with acute ischaemia of visceral organs and lower limbs were excluded from the study. Clinical characteristics of the patients are shown in Table 1.

In the preoperative period we evaluated the aortic diameter in the thoracic and abdominal portions, the ratio of the diameters of the true and false lumens, the level of intimal fenestration, also assessing the renal function. A surgical approach was made by means of thoracofrenolumbotomy along the 5th intercostal space. In order to provide the operation till 2014 we used a left-atrial – femoral bypass with connection according to the scheme: left atrium – femoral artery (LAFB), however later on, after 2014, we transferred to a more contemporary scheme of support: artificial circulation (AC) with peripheral connection according to the scheme: femoral vein – femoral artery. Such scheme makes it possible, in difficulties of exposing the aortic arch, to perform hypothermic circulatory arrest for establishing an anastomosis between the aortic arch and the graft. Obligatorily in all operations we used single-lung ventilation and drainage of the cerebrospinal fluid. The function of the spinal cord during the operation was assessed by the method of evoked motor potentials.

Parameters	Values
Age, years	51 (44; 61)
Male patients (%)	11 (69)
Diameter of the aorta in the thoracic portion (max.), mm	63 (56; 75)*
Diameter of the aorta in the abdominal portion (max.), mm	28 (26; 33)*
Second stage after the Borst operation, n (%)	4 (25)
Dissection of visceral arteries, n (%)	8 (50)*

* – by the findings of MSCT angiography.

All patients underwent reconstruction of the thoracoabdominal portion of the aorta in combination with open implantation of the Djumbodis uncoated metal stent into the area of lower thoracic and visceral arteries. Directly the stage of stent implantation took place immediately after establishing an anastomosis between either the graft and aortic arch distal to the left subclavian artery or the graft and the “elephant trunk” in case of performing the second stage after the Borst operation. In case of using hypothermic circulatory arrest perfusion of the upper half of the body was renewed after a preliminarily formed lateral branch of the graft of the thoracic artery, and perfusion of the lower part of the body was discontinued at this moment. When using normothermic perfusion, after formation of the proximal anastomosis with the aortic arch, AC was stopped and perfusion of the upper half of the body was provided by own cardiac output. The stent was placed under either videoendoscopic or roentgenoscopic control (C-arch) into the true lumen of the aorta from the level Th10–Th11 and distally in conditions of no perfusion below the diaphragm. The true lumen was identified visually after dissecting the aorta above the diaphragm, in accordance with the CT-image of the dissection (Fig. 1).

Thereafter, depending on the aortic size in the abdominal portion, the operation was terminated by performing an anastomosis above the diaphragm – type A correction, or prosthetic repair of the thoracic portion was supplemented by prosthetic repair of the infrarenal portion – type B correction (Fig. 2). In the postoperative

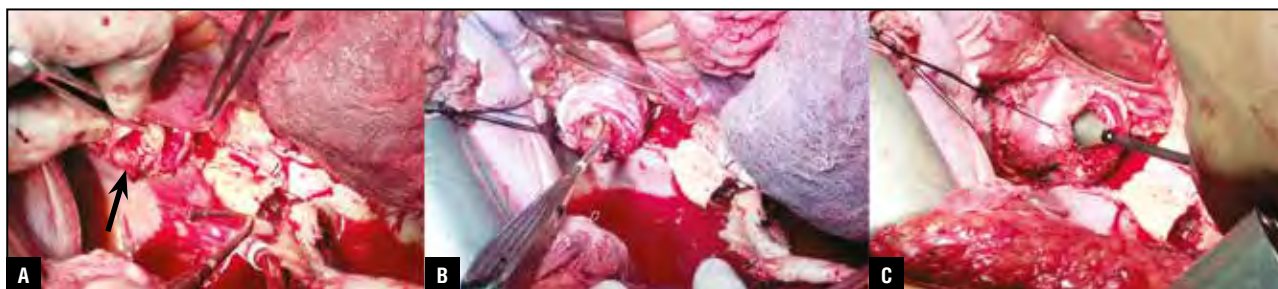


Fig. 1. Stages of stent implantation. A – identification of the true lumen (indicated by an arrow), B – reinforcing the aorta according to the “double sandwich” technique, C – implantation of the Djumbodis stent.

Data of intra- and postoperative period	
Parameters	Values
Type A correction, n	5
Type B correction, n	11
Volume of postoperative blood loss, ml	456±120.9
Re-operations for achieving haemostasis, n (%)	2 (13)
Mean duration of stent implantation, min	9.3±1.8
Cases of malperfusion of visceral organs or lower limbs, %	0
Duration of artificial pulmonary ventilation, hours	58 (37; 76)
Length of hospital stay, days	23 (16; 28)
Renal failure, hepatic insufficiency, % (n)	6.3 (1)
Neurological complications, % (n)	0
In-hospital mortality rate, % (n)	6.3 (1)
Thrombosis of the false lumen at the level of stent deployment	81 (13)
– type A correction, n (%)	8 (72.7)
– type B correction, n (%)	5 (100)

period the patients received standard therapy: antibiotic therapy, antihypertensive, haemostatic therapy.

RESULTS

In the postoperative period prior to discharge from hospital all patients were subjected to MSCT angiography of the thoracic and abdominal portions of the aorta in order to control patency of the true and false lumens, patency of visceral arteries, to assess the aortic diameter, the presence or absence of thrombosis. In patients with type B correction, thrombosis of the false lumen was revealed in 5 cases (100% of the number of the performed operations of this type), in patients with type A correction, thrombosis of the false lumen was detected in 8 cases (72.7% of the number of the performed operations of this type).

The data of the postoperative period are shown in Table 2.

There was 1 (6.3%) case of death at the hospital stage occurring in the group of type A correction. Death was caused by a perioperative iatrogenic lesion of the left ventricle followed by the development of uncontrolled haemorrhage. No cases of either neurological deficit, malperfusion of visceral organs, or lower-extremity ischaemia were registered. There was one case of acute renal failure requiring the connection of renal replacement therapy in the postoperative period in a patient with baseline chronic renal insufficiency.

DISCUSSION

Prosthetic repair of the thoracoabdominal portion of the aorta still remains an important yet insufficiently solved problem of cardiac surgery with high rates of both perioperative complications and mortality. Thus, according to the findings of Le Maire, Coselli, having analysed more than 800 cases concerning aneurysms of the thoracoabdominal portion of the aorta at specialized

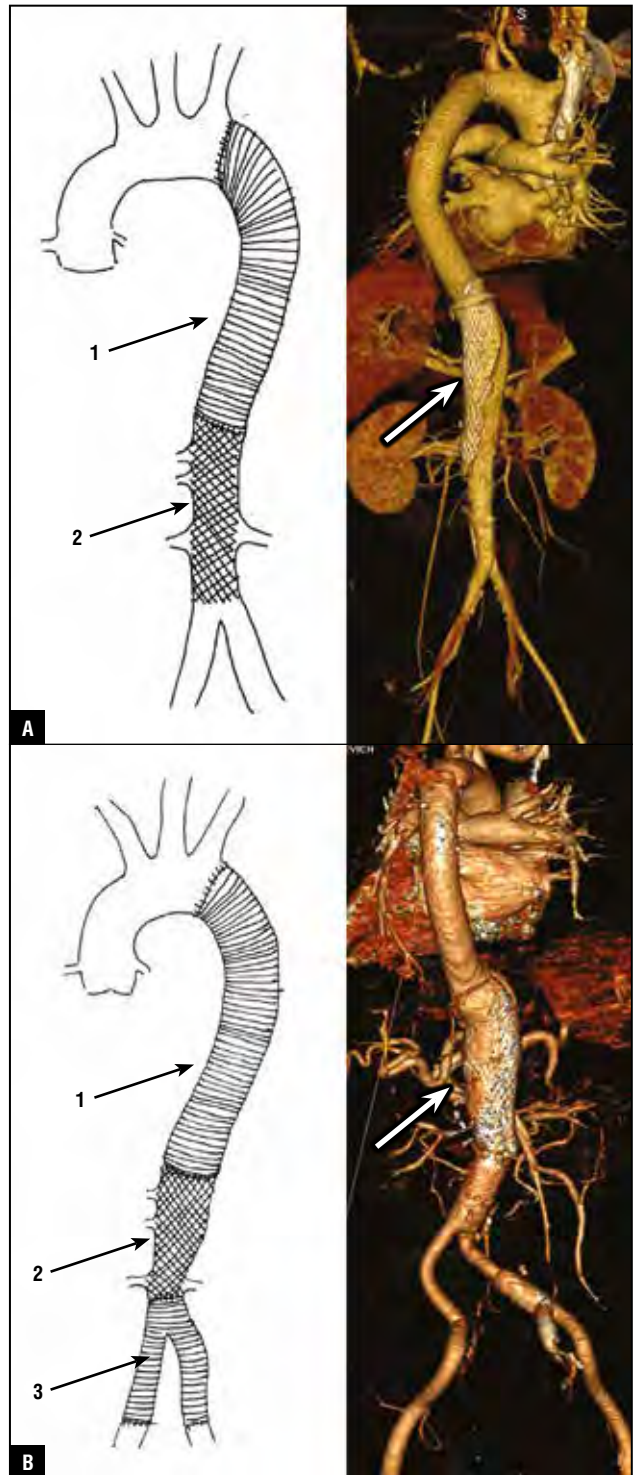


Fig. 2. A, B. Possible variants of prosthetic repair of the thoracoabdominal portion of the aorta (arrows indicate the zone of stent implantation). 1 – tubular Dacron graft, 2 – uncovered metal stent, 3 – bifurcation stent.

centres, the perioperative mortality rate is more than 8%, with the neurological complications rate amounting to 6.3% [8]. And in the centres with small experience in performing similar operation, according to the findings of Bavaria, the rate of spinal complications may reach

23–25 % [15]. Such results compel surgeons to search for less invasive and traumatic techniques for appropriate management of the pathology involved. Hybrid prosthetic repair of the thoracoabdominal portion of the aorta is one of such methods. Simultaneous stenting of the abdominal portion of the aorta makes it possible to avoid reimplantation of visceral and spinal branches, and, consequently, to reduce the duration of visceral organs ischaemia, to decrease the number of anastomoses created. As shown by own experience, as well as by our colleagues' experience, in cases of dilatation of the supradiaphragmal portion alone, it is possible to perform thoracotomy without additional dissection of the diaphragm, which, unconditionally, decreases the traumatic nature of the intervention and diminishes the possibility of postoperative haemorrhage and respiratory complications, as well as diminishes the risk of renal insufficiency and multiple organ failure [16, 17]. The cause of making possible the use of this type of stents in the position of visceral branches and critical zone of spinal arteries during correction of thoracoabdominal aortic dissections is as follows: there has been gained sufficiently wide experience in using uncoated metal stents for correction of type A dissection with implantation of the stent into the aortic arch, having demonstrated that even in case of a chronic process and rigidity of the false lumen, re-direction of the main blood flow into the true lumen makes the flow to be laminar and creates conditions for formation of thrombi in the false lumen of the aorta [13, 14, 18]. At the same time, the size of the mesh of the uncoated metal stent of the aorta amounts to approximately 1 cm in the completely expanded state, which does not create obstacles to blood flow in large branches in the zone of implantation [18, 19]. Hence, currently, there are hybrid technologies which are optimal in treatment of distal aortic dissection from the point of view of diminishing intraoperative trauma, decreasing the number of perioperative complications, and without detriment to the radicality. Undoubtedly, more complete assessment of this type of intervention requires a larger sample size and evaluation of remote results.

ЛИТЕРАТУРА/REFERENCES

1. *Alsov S.A., Khvan D.S., Sirota D.A., et al.* Acute proximal aortic dissection with rupture tear of the ostium of the right coronary artery. *Circulation Pathology and Cardiac Surgery*. 2015; 19: 3: 114–117 [in Russian].
2. *Crawford E.S., DeNatale R.W.* Thoracoabdominal aortic aneurysm: observations regarding the natural course of the disease. *J. Vasc. Surg.* 1986; 3: 578–582.
3. *Grabengoger M., Alfonso F., Bachet J., et al.* Thoracic Endovascular Aortic Repair (TEVAR) for the treatment of aortic diseases: a position statement from the European Association for Cardio-Thoracic Surgery (EACTS) and the European Society of Cardiology (ESC), in collaboration with the European Association of Percutaneous Cardiovascular Interventions (EAPCI). *Eur. Heart. J. Advance*. 2012; May 4: 2–8.
4. *Tsai T.T., Fattori R., Trimarchi S., et al.* Long-term survival in patients presenting with type B acute aortic dissection: insights from the International Registry of Acute Aortic Dissection. *Circulation*. 2006; 114(21): 2226–2231.
5. *Bickerstaff L.K., Pairolero P.C., Hollier L.H., et al.* Thoracic aortic aneurysms: a population-based study. *Surgery*. 1982; 92: 110.
6. *Tan M.E., Morshuis W.J., Dossche K.M., et al.* Long-term results after 27 years of surgical treatment of acute type aortic dissection. *Ann. Thorac. Surg.* 2005; 80: 523–529.
7. *Halstead J.C., Meier M., Etz C., et al.* The fate of the distal aorta after repair of acute type A aortic dissection. *J. Thorac. Cardiovasc. Surg.* 2007; 133: 127–135.
8. *LeMaire S.A., Price M.D., Green S.Y., et al.* Results of open thoracoabdominal aortic aneurysm repair. *Ann. Cardiothorac. Surg.* 2012; 1(3): 286–292.
9. *Schepens M.A., Heijmen R.H., Ranschaert W., et al.* Thoracoabdominal aortic aneurysm repair: Results of conventional open surgery. *Eur. J. Vasc. Endovasc. Surg.* 2009; 37: 640–645.
10. *Svensson L.G., Kouchoukos N.T., Miller D.C., et al.* Expert consensus document on the treatment of descending thoracic aortic disease using endovascular stent-grafts. *Ann. Thorac. Surgery*. 2008; 85(1 Suppl): 1–41.
11. *Eggebrecht H., Nienaber C.A., Neuhauser M., et al.* Endovascular stent-graft placement in aortic dissection: a meta-analysis. *J. Thorac. Cardiovasc. Surg.* 2009; 138(4): 865–872.
12. *Chuter T.A.* Fenestrated and branched stent-grafts for thoracoabdominal, pararenal and juxtarenal aortic aneurysm repair. *Semin. Vasc. Surg.* 2007; 20: 90–96.
13. *Chernyavsky A.M., Lyashenko M.M., Alsov S.A., et al.* Hybrid approach in surgery of proximal-type aortic dissections. *Angiology and Vascular Surgery*. 2014; 20: 3: 41–47 [in Russian].
14. *Chernyavsky A.M., Alsov S.A., Lomivorotov V.V., et al.* Hybrid approach in treatment of chronic proximal aortic dissection. *Cardiology and Cardiovascular Surgery*. 2012; 6: 103–106 [in Russian].
15. *Messe S.R., Bavaria J.E., Mullen M., et al.* Neurologic outcomes from high risk descending thoracic and thoracoabdominal aortic operations in the era of endovascular repair. *Neurocrit. Care*. 2008; 9: 344–351.
16. *Belov Yu.V., Charchyan E.R., Soborov M.A.* Hybrid reconstructive interventions in distal aortic dissection. *Angiology and Vascular Surgery*. 2011; 4: 101–107 [in Russian].
17. *Belov Yu.V., Charchyan E.R., Soborov M.A.* “Hybrid” method of achieving haemodynamic correction in patients presenting with type B aortic dissection.

- Cardiology and Cardiovascular Surgery. 2011; 2: 80 [in Russian].
18. **Ius F., Vendramin I., Mazzaro E., et al.** Transluminal Stenting in Type A Acute Aortic Dissection: Does the Djumbodis System Have Any Impact on False Lumen Evolution? *Ann. Thoracic. Surg.* 2010; 90: 1450–1456.
19. **Iannelli G., Tommaso L., Cirillo P.** Treatment of Residual Type A Aortic Dissection With Implantation of the Djumbodis System: Is Purely Endovascular Treatment Becoming a Reality? *J. Endovascular. Therapy.* 2011; 18: 368–373.
-
-